



**Marc Goldstein, MD, DSc (hon), FACS**

Matthew P. Hardy Distinguished Professor of Reproductive Medicine and Urology  
Surgeon-in-Chief, Male Reproductive Medicine and Surgery

Cornell Institute for Reproductive Medicine  
525 East 68th Street, Box 580  
New York, NY 10065

Telephone: 212-746-5470

Fax: 212-746-0977

mgoldst@med.cornell.edu

www.maleinfertility.org

## POST-VASECTOMY INSTRUCTIONS

1. Apply an ice pack intermittently to the scrotum for 48 hours after the procedure to help decrease discomfort and swelling. Some scrotal swelling and bruising is common and will resolve in a few days.
2. A small amount of bright red bleeding from the sites is to be expected. Do not be alarmed. If you think the amount is excessive, call my office.
3. You may experience a dull ache in the testicles and groin. At the time of discharge from the hospital you will be given a prescription for pain medication to use as needed. You may use Tylenol for pain if you choose, but Aspirin and Aspirin-containing medications, non-steroidal anti-inflammatory products and herbal supplements that may effect bleeding should be avoided.
4. Wear a scrotal supporter at all times (even when sleeping) for 48 hours after the procedure. You may remove it to shower.
5. You should remain at bed rest for 24 hours. You may resume light work in 2-3 days. No heavy work, sports or lifting are allowed for one week. No driving until Monday. (You may be a passenger.)
6. Sexual intercourse may be resumed in one week. Contraception must be used.
7. There may be blood in the first few ejaculations after vasectomy. Do not be alarmed. This will clear after 3 – 4 days.
8. You will not be sterile immediately after vasectomy. It usually takes 6 to 12 weeks or approximately 15 – 20 ejaculations to clear out old sperm.
9. **Contraception must be used until the absence of sperm is confirmed by two consecutive semen analyses done 6 weeks and 12 weeks after the vasectomy.**

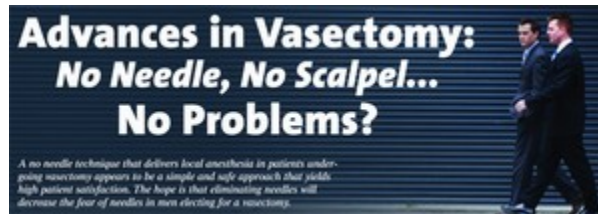If you have any questions, please feel free to call my office.

# Physician's Weekly®

© 2006 Physician's Weekly, LLC

March 6, 2006 Vol. III, No. 10

## This Week's Lead Story



### Advances in Vasectomy: No Needle, No Scalpel... No Problems?

*A no needle technique that delivers local anesthesia in patients undergoing vasectomy appears to be a simple and safe approach that yields high patient satisfaction. The hope is that eliminating needles will decrease the fear of needles in men electing for a vasectomy.*

Vasectomy is the one of the safest and most dependable methods of permanent contraception available to men. It is estimated that about 500,000 vasectomies are performed each year in the United States. With the traditional technique for vasectomy, surgeons usually require 20 to 30 minutes to complete the procedure. Patients can return to work fairly quickly, but they do have some pain. Moreover, research has indicated that 1% of traditional procedures have complications, which include bleeding, hematoma, and infection.

In 1975, Li Shunqiang, MD, developed the no scalpel vasectomy in China. Since that time, the procedure has been adopted in the United States and about 15 million Americans have undergone a no scalpel vasectomy. In addition to being an effective contraceptive, clinical studies have shown that it is associated with a 10-fold reduction in complications when compared with standard vasectomy.

### Reducing Pain & Complications With a New Approach

A no needle, no scalpel vasectomy is a unique and nearly painless technique for anesthetizing the scrotal skin and the vas deferens. An anesthetic solution is sprayed through the skin and around the vas deferens using a high pressure jet injector (Table 1). According to Marc Goldstein, MD, FACS, patients describe the sensation of the no needle, no scalpel procedure as "a gentle snap of a rubber band against the scrotal skin." He says "the technique delivers local anesthesia for vasectomy with less pain, which is important because most men are afraid of the needle puncture involved in traditional vasectomy. After the procedure, patients often return to their daily routine within just a few days because there is little or no pain and because no stitching is involved."

Additionally, the no needle, no scalpel vasectomy takes an average of about seven minutes to complete for an experienced surgeon, according to Dr. Goldstein. "Another key advantage is that it requires the use of less lidocaine. Only 0.6 cc of an anesthetic

are required because it's more directly targeted to the treatment area [Table 2]. A cone-shaped distribution of the anesthetic is administered and provides effective anesthesia. In turn, the patient experiences much less postoperative swelling."

## Learn the No Scalpel Approach First

According to Dr. Goldstein, mastering the no scalpel procedure is necessary before surgeons can begin to learn the no needle, no scalpel vasectomy. "The traditional vasectomy is simple in that we can find the vas deferens more easily when a large incision is made. But the no scalpel approach is all based on feeling the vas deferens and trapping it between the fingers using the three-finger fixation technique. It's a learning curve that requires much experience."

Accurate placement of the high pressure jet injector is important when learning the no needle, no scalpel vasectomy, according to Dr. Goldstein. "Surgeons can actually inject themselves in the finger with the anesthetic if they fail to place the injector in exactly the right place. However, surgeons can minimize this risk as they become more experienced using the technology."

## Can All Patients Receive No Needle, No Scalpel Vasectomy?

According to Dr. Goldstein, most patients seeking a vasectomy can undergo the no scalpel approach. "The only patients who would be excluded from having this procedure would be those who have had extensive prior scrotal surgery. Previous surgery can make it difficult for surgeons to totally visualize the vas deferens. Also, there may be a contraindication if the patient exhibits prior scarring from scrotal surgery or if they have cryptorchidism. In the 20 years that I have been performing no scalpel vasectomy, I have had just two patients who have been unable to have the procedure."

With regard to the no needle, no scalpel vasectomy, Dr. Goldstein says that patients are eager to undergo this less invasive procedure. "However, only about two or three institutions in the United States currently have the capability to perform the no needle, no scalpel vasectomy. It may take some time before the procedure becomes more widely available because physicians must acquire the instrumentation and learn the proper technique. The instruments must also be maintained perfectly in order to be utilized safely and effectively. It's a good practice to have at least two high pressure jet injectors so that an alternative is available should one fail during the procedure."

Table 1 The No Needle Jet Injection Technique	
The jet injection technique uses an instrument that generates a high pressure spray that forces anesthetic solution through the skin and surrounding vascular tissues, providing painless anesthesia and rarely requiring application of additional anesthetic.	
• Approximately 4-5 cc of anesthetic solution is loaded into a filling chamber that is fixed to the jet injector.	• The groove in the spacer on the tip of the jet indicator is placed firmly over the right vas on the median raphe at the junction of the upper third and lower two thirds of the scrotum.
• A spacer with a notch at the tip of the jet injector fits over the vas deferens and allows enough distance for the spray of anesthetic to spread out in a cone-shaped distribution prior to and just after penetrating the skin.	• Three sprays of anesthesia are applied along the left lateral aspect of the median raphe about 4-5 mm apart.
• The instrument is then primed by pumping the lever and firing several times to ensure it is functioning properly.	• The same technique is used for the left vas deferens except that three injections are applied to the right lateral aspect of the median raphe adjacent to the previous injections.
• The right vas deferens is grasped using the three finger technique and brought to the surface of the scrotal skin at the median raphe.	• The jet injection is effective because the anesthetic solution disperses in an inverted cone-shaped area, affecting all of the tissues to a depth of 4-4.5 mm from the skin surface.
• The skin over the median raphe only has to be swabbed with an alcohol pad prior to the administration of analgesia.	• No skin wheal or local edema is present at the injection site, making no scalpel vasectomy easier to perform.

Source: Marc Goldstein, MD, FACS

Table 2

## Comparing No Scalpel Vasectomies

According to a study published in the May 2005 Journal of Urology, the no needle, no scalpel vasectomy offers significant advantages to the no scalpel vasectomy:

Per Vasectomy Conventional Needle	No Scalpel Vasectomy	No Needle, No Scalpel Vasectomy
Average lidocaine volume	6 cc	0.6 cc
Average time to anesthesia onset	60-90 seconds	10-20 seconds
Average cost of anesthesia*	\$0.79 US Dollars	\$0.07 US Dollars

\* Not including capital outlay for injection.

Source: Wilms KS, U PS. No-needle jet anesthetic technique for no-scalpel vasectomy. J Urol. 2005;173:1677-1680.



## Marc Goldstein, MD, FACS

**Professor of Reproductive Medicine  
& Urology**

**Weill Medical College of Cornell  
University**

**Surgeon-in-Chief**

**Male Reproductive Medicine  
and Surgery**

**Executive Director**

**Men's Service Center of the Cor-  
nell Institute for Reproductive  
Medicine**

**Director, Center for Male Reproduc-  
tive Medicine and Microsurgery**

**New York-Presbyterian Hospital/  
Weill Cornell Medical Center**

## REFERENCE LINKS:

Weiss RS, Li PS. No-needle jet anesthetic technique for no-scalpel vasectomy. *J Urol.* 2005;173:1677-1680.

Li PS, Goldstein M, Shu J, Huber D. The no-scalpel vasectomy. *J. Urol.* 1991;145:341-344.

Jow WW, Goldstein M. No-scalpel vasectomy offers minimal invasiveness. *Contem. Obstet Gynecol.* 1996;60:112-121.

Goldstein M, Li PS, Matthews GJ. Microsurgical vasovasostomy: The microdot technique of precision suture placement. *J. Urol.* 1998;159:188-190.

Boorjian S, Lipkin M, Goldstein M. Robotic microsurgical vasovasostomy and Vasoepididymostomy: A prospective randomized study in a rat model. *J. Urol.* 2004;171:304-306.

Chan PT, Goldstein M. Superior outcomes of microsurgical vasectomy reversal in men with the same female partners. *Fertil Steril.* 2004;81:1371-1374.

Nath NC. No-scalpel vasectomy at a glance. *J Indian Med Assoc.* 2005;103:273-274, 276-277, 288.

Nemani PK. No-scalpel vasectomy--hope for future: Historical aspects. *J Indian Med Assoc.* 2005;103:270, 272.

Chen KC, Peng CC, Hsieh HM, Chiang HS. Simply modified no-scalpel vasectomy (percutaneous vasectomy)--a comparative study against the standard no-scalpel vasectomy. *Contraception.* 2005;71:153-156.

# No-Needle Anesthetic Appeals to Needle-Phobic Vasectomy Patients

## Reducing Anxiety May Lead to More Vasectomies

by Theodore V. Benderev, M.D.

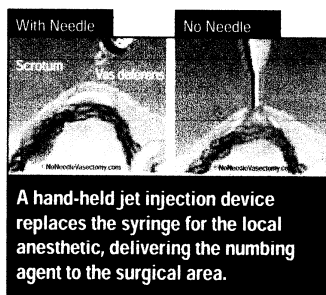
Every urologist recognizes that most men are moderately apprehensive about a vasectomy procedure. And while over 500,000 men decide to have this simple, safe procedure each year, many more men think about the idea, but steer away from a vasectomy for various reasons—some real and some imagined. In the United States, of the 1.5 million surgical permanent sterilization procedures, two-thirds are tubal ligation and only one-third are vasectomies. This is even more remarkable when one considers that in Canada the ratios are reversed.

There is a new technique that could dramatically increase vasectomies in the United States over the current favorite alternative of tubal ligation. This relatively simple technique is catching the attention of both patients and doctors, answering one of the classic objections about the vasectomy procedure—the needle. This new anesthetic delivery method removes what many men consider to be the most painful part of the vasectomy: the two needle sticks for delivery of the lidocaine. The availability of a no-needle anesthetic technique may decrease the fear of pain in men and enhance the popularity of vasectomy worldwide.

### Jet Spray Device

Five thousand patients in the United States and Canada have already received a jet injection spray instead of the traditional needle to deliver anesthetic to the skin and underlying vasa. In 2001, Charles L. Wilson, M.D. initially described this technique for vasectomy in a letter of communication.

Although relatively new to vasectomy procedures, similar no-needle techniques are commonly used for anesthesia in dentistry and many other areas of medicine with wide acceptance by doctors and patients. According to physician experts, this



technique lowers patient fears, reduces pain, and simplifies procedures.

### Research Study Reported

The findings of a study of 465 patients titled "No-Needle Jet Anesthetic Technique for No-Scalpel Vasectomy" was presented at the American Urology Association Annual Meeting this year in San Antonio, and was published in the *Journal of Urology* in May 2005. The paper describes a jet-injector device that produces almost instant anesthesia with an average total lidocaine dosage of only .6cc. The average visual analog scale score for the pain of the jet injection itself was 1.71 of 10. The average visual analog scale score for the pain of subsequent vasectomy during the surgical procedure was 0.66 of 10 (median 0.2). No patients experienced hematomas.

Doctors who described the technique and published their findings—Ronald S. Weiss, M.D. and Philip S. Li, M.D.—conclude this to be a "simple and safe approach with high patient satisfaction, as reflected in low pain scores."

### Virtually Painless Option

My own skepticism about how a topical application can achieve such deeper anesthesia was dispelled following observation of the technique. Now, after use

in more than 200 patients, the no-needle vasectomy has become the standard technique in my practice. The following patient comment is typical of the experience: "For me, it was completely painless. No-needle vasectomy was even better than what I expected." The learning curve for jet anesthesia is relatively short, though it is important that the surgeon be skilled in some form of minimally invasive vasectomy, such as the no-scalpel vasectomy. Also, precautions outlined in the manual must be taken to avoid self-injury from the device.

Anesthesia without a needle has been welcomed by many men. Dr. Marc Goldstein, an international authority on vasectomy at Cornell University, reported, "My patients have responded exceptionally well to the no-needle approach for vasectomy."

### Where Will the Public Find Out About This New Technique?

Experience tells us that as more is written about new techniques such as the no-needle vasectomy in the traditional media, men and their families will search for information from the Internet.

There are two Web sites available online for information about vasectomy and no-needle vasectomy. These sites are **vasectomy.com**, established in 1996 and currently the leading site for vasectomy and related information, and **noneedlevasectomy.com**, with a special focus on this technique.

Public interest and acceptance of the procedure is expected to grow as this technique becomes more widely available—answering the significant objection of many prospective patients. With tubal ligations out-numbering vasectomies in the U.S. by two to one, this technique may finally help more men decide to have a vasectomy rather than a couple opting for female sterilization. And, as public knowledge and response increases, marketing-aware practices will recognize how to change their patient mix to better serve the needs of the public as well as bolster their overall revenues.

*Theodore V. Benderev, M.D., is a board-certified urologist and medical director of the multispecialty Incontinence and Pelvic Support Institute in Mission Viejo, CA. In addition to his pelvic reconstructive surgeries, Dr. Benderev dedicates each Friday to vasectomy procedures and uses no-needle anesthesia.*

### We Know Coding, We Know Billing, We Know Urology

#### PRSUROLOGY SERVICE CORPORATION

##### Billing Solutions

- Practice Management System
- Claim Scrubber
- Electronic Medical Records
- Full Service Billing
- Billing Lite
- Insurance Collections

##### Consulting Services

- Fee Schedule and Contract Analysis
- Benchmarking—Physician and Payer
- Compliance Plan Development
- E/M Audits / Workshop
- Practice Expansion Planning
- Patient Marketing
- Modifier Use
- Surgical Coding
- Form Design
- Practice Flow
- Human Resource Support

1675 Larimer Street, Suite 410,  
Denver, Colorado 80202  
Ph 800-574-1936 Fx 303-468-0345  
[www.prsurosc.com](http://www.prsurosc.com)



## THE NO-SCALPEL VASECTOMY

SHUNQIANG LI, MARC GOLDSTEIN,\* JINBO ZHU AND DOUGLAS HUBER

*From the Chongqing Family Planning Scientific Research Institute, Chongqing, China, and The James Buchanan Brady Foundation, Department of Surgery, Division of Urology, The New York Hospital-Cornell Medical Center, The Population Council, and the Association for Voluntary Surgical Contraception, New York, New York*

### ABSTRACT

A refined method of delivering the vas deferens for vasectomy has been developed and used in China since 1974. This method eliminates the scalpel, results in fewer hematomas and infections, and leaves a smaller wound than conventional techniques. An extracutaneous fixation ring clamp encircles and firmly secures the vas without penetrating the skin. A sharp curved hemostat punctures and dilates the scrotal skin and vas sheath. The vas is delivered, cleaned and occluded by the surgeon's preferred technique. The contralateral vas is delivered through the same opening. The puncture wound contracts to about 2 mm., is not visible to the man and requires no sutures for closure. The reported incidence of hematoma in 179,741 men followed in China was 0.09%. No hematomas or infections were identified in the first 273 procedures performed by a surgeon in the United States. The operating time in China and for the last 50 United States procedures has ranged from 5 to 11 minutes. The disadvantage of the technique is the hands-on training and number of cases necessary to gain proficiency. However, the advantages for surgeons and patients should enhance the popularity of vasectomy.

KEY WORDS: vasectomy; vas deferens; sterilization, sexual; contraception

Vasectomy is one of the safest, simplest and most effective methods of permanent contraception. Although it is less expensive and associated with much lower morbidity and mortality than tubal ligation, far fewer vasectomies are performed than female sterilizations worldwide. Some men will not consider vasectomy because they fear the trauma, pain and possible complications associated with scrotal surgery. Conventional techniques of vasectomy require incision of the scrotum with a scalpel followed by dissection and delivery of the vas deferens. At the Chongqing Family Planning Scientific Research Institute in the Sichuan province of China a new method for gaining access to the vas deferens for vasectomy was developed in 1974.<sup>1</sup> This method eliminates the scalpel, results in fewer hematomas and infections, and leaves a much smaller wound than conventional methods of accessing the vas deferens for vasectomy. The first United States surgeon to be trained in the technique by Doctor Li (in 1986) is one of the authors (M. G.) who performed the United States procedures discussed in this report.

### SURGICAL TECHNIQUE

**Preparation.** The scrotal skin is shaved and the penis is retracted upward onto the abdomen by placing a rubber band around the penis just under the glans and securing it with a clamp to the patient's shirt or gown. The skin is prepared with a warm antiseptic solution. A relaxed scrotum facilitates the procedure and, therefore, cold antiseptic solutions and a cold operating room should be avoided.

**Local anesthesia.** With the surgeon standing on the right side of the patient, the vas deferens is separated from the internal spermatic vessels and manipulated to a superficial position under the median raphe at the junction of the middle and upper thirds of the scrotum. The right vas is firmly trapped over the middle finger of the left hand and under the index finger and

thumb (fig. 1, A). A superficial skin wheal is raised using a 1 or 1.5-inch fine gauge needle and 2% plain lidocaine. The needle is then advanced in the perivascular sheath toward the external inguinal ring and 2 to 5 ml. lidocaine are injected, which effects a vasal nerve block away from the actual vasectomy site. The left vas deferens is fixed under the previous skin puncture site and anesthetized using the same 3-finger technique (fig. 1, B). The original skin wheal is pinched to reduce local edema.

**Fixation and delivery of the vas.** After both vasa have been anesthetized, the right vas is again fixed under the site of the skin wheal with the left hand using the 3-finger method (fig. 1). The extracutaneous vas deferens fixation ring clamp (fig. 2, A) is grasped with the right hand and pressed exactly perpendicularly onto the skin immediately overlying the midline of

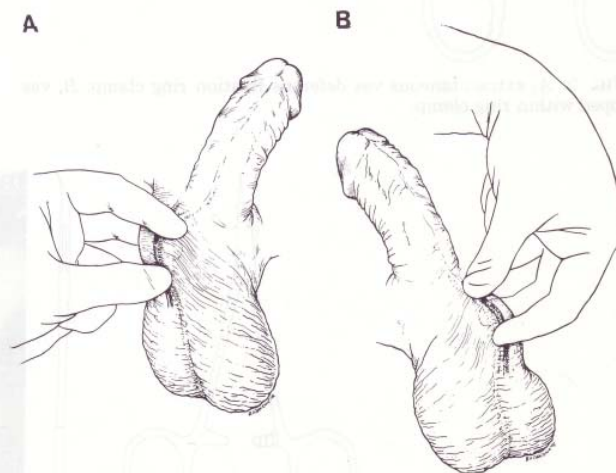


FIG. 1. A, 3-finger technique for fixation of right vas beneath median raphe. B, 3-finger technique for fixation of left vas beneath median raphe.

Accepted for publication August 22, 1990.

\*Requests for reprints: Division of Urology F900, The New York Hospital-Cornell Medical Center, 525 E. 68th St., New York, New York 10021.



the vas. The clamp is opened while exerting firm pressure downward, thus stretching the scrotal skin tightly over the underlying vas. The clamp is then locked around the vas. The cantilevered feature of this specially designed clamp prevents damage to the scrotal skin even when the clamp is locked tightly. The ring clamp is now grasped in the left hand and the entrapped vas is elevated with the left index finger pressing downward to tighten the scrotal skin just beyond the tip of the clamp (fig. 2, B).

A curved mosquito hemostat with the serrations ground off and the point sharpened (fig. 3, A) was designed in China as a dissecting clamp. With the concavity of the dissecting clamp facing posteriorly, the left blade of the opened dissecting clamp is used to pierce the scrotal skin, vas sheath and vas wall where the vas is most superficial and prominent (fig. 3, B). The vas should be pierced exactly in the midline and the angle of the dissecting clamp to the longitudinal axis of the vas should be 45 degrees.

The left blade of the dissecting clamp is withdrawn, the instrument is closed and both blades are introduced through the same puncture hole at the same angle as described previously. The blades of the dissecting clamp are gently opened, spreading all layers down to the bare vas wall. Using the right blade of the dissecting clamp, the bare vas wall is skewered at a 45-degree angle and the dissecting clamp is rotated laterally 180 degrees (fig. 4). The vas is now delivered through the puncture hole while simultaneously releasing the ringed extracutaneous fixation clamp (fig. 5, A). The ring clamp is used to

grasp the delivered vas (fig. 5, B). The dissecting clamp is used to strip gently the sheath and vasal vessels away from the vas, yielding a clean segment of vas at least 2 cm. long (fig. 6).

At this point the vas is divided and occlusion is effected in whatever manner the surgeon prefers. In China occlusion is performed with double silk ligatures, removal of a 1 cm. segment and sealing of the abdominal end in its sheath with a silk ligature. In the New York series the lumen of the vas was cauterized for a distance of 1 cm. in each direction after removing a 1 cm. segment and the abdominal end was sealed in its sheath with a single medium metal hemoclip. The cautery and clip technique has the advantage of eliminating the need for a surgical assistant.

After occlusion the ends of the right vas are returned to the scrotum and the left vas is fixed directly under the same previously made puncture hole using the 3-finger technique (fig. 1, B). If local edema makes fixation of the skin and underlying vas impossible, the ring clamp may be placed through the puncture hole, encircling the vas and its sheath without the overlying skin. The remainder of the procedure is identical to that described for the left side.

After both vasa have been occluded and returned to the scrotum, the puncture site is pinched tightly for a minute and inspected for bleeding. The puncture hole will have contracted and be invisible to the patient. Antibiotic ointment is applied to the puncture hole and sterile dressing is held in place with a snug fitting scrotal supporter.

#### RESULTS

More than 8 million no-scalpel vasectomies have been done in the Sichuan province of China. In 1 study followup exami-

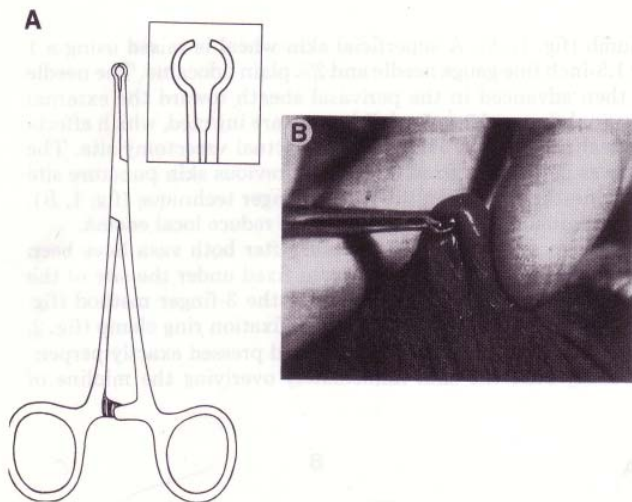


FIG. 2. A, extracutaneous vas deferens fixation ring clamp. B, vas trapped within ring clamp.

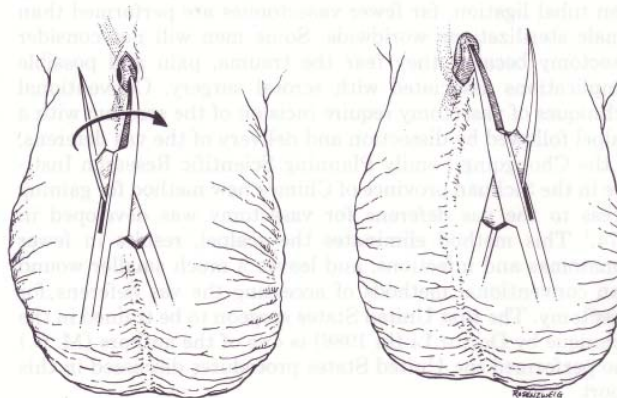


FIG. 4. Vas well is skewered and dissecting clamp is rotated 180 degrees.

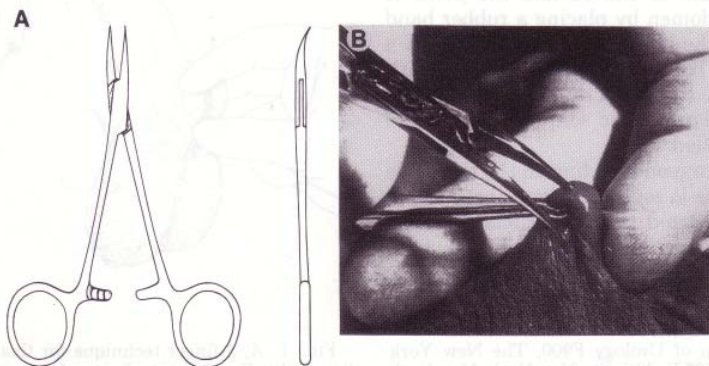


FIG. 3. A, dissecting clamp. B, puncture of skin and vas sheath



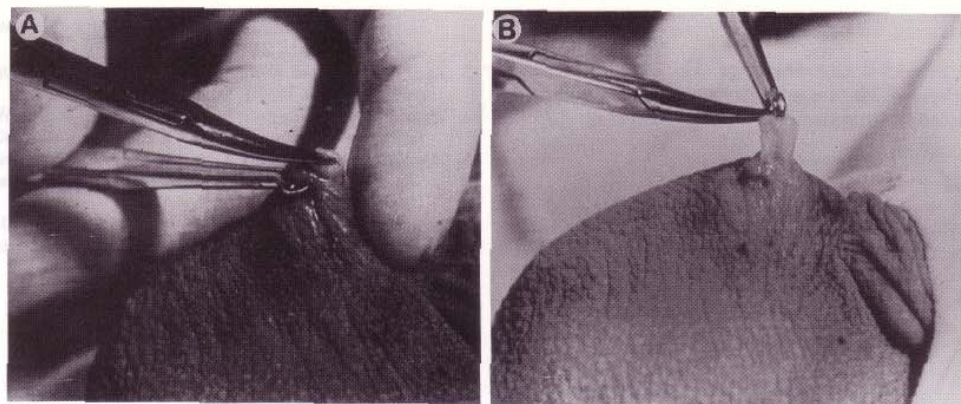


FIG. 5. Delivery of vas

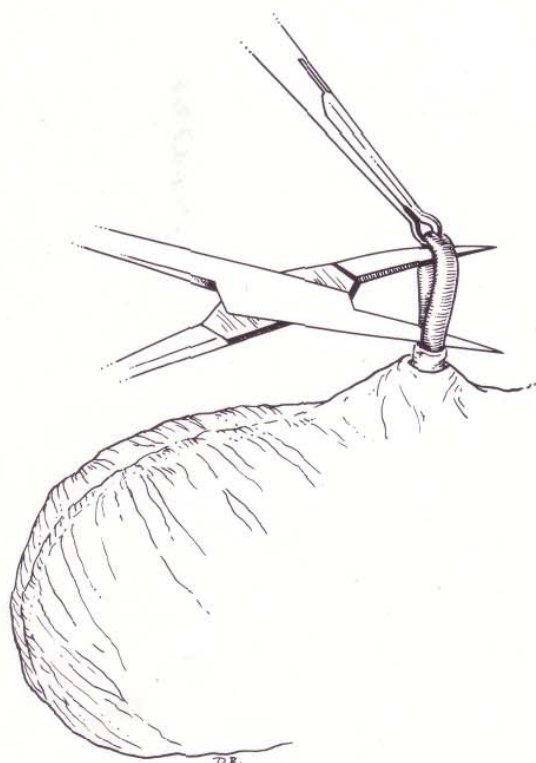


FIG. 6. Sheath and vasal vessels stripped from vas

Complications after no-scalpel vasectomy

	No.	Hematoma (%)	Infection (%)
China	179,741	160 (0.09)	1,630 (0.91)
New York	238	0	0

nations were performed on 179,741 men. Hematomas were identified in 160 men (0.09%) and superficial infections in 1,630 men (0.91%). Beginning in 1985, 273 men have undergone the no-scalpel vasectomy at the New York Hospital-Cornell Medical Center. No hematomas or infections were identified among the 238 men who returned for followup examinations (see table). The operating time for the procedures performed in China and the last 50 procedures performed at the New York Hospital-Cornell Medical Center ranged from 5 to 11 minutes.

This operating time represents a 50% reduction for the New York surgeon compared to the operating time for the conventional incisional vasectomies.

#### DISCUSSION

Vasectomy is safer, quicker and less costly than tubal ligation in women. Despite this many more tubal ligations are performed worldwide than vasectomies. Some men equate vasectomy with castration or loss of masculinity, while others fear the surgical knife, pain and discomfort attendant to vasectomy. A focus group sponsored by the Association for Voluntary Surgical Contraception found that men who had undergone conventional vasectomy experienced more pain and discomfort during and after the procedure than they had been led to expect by the operating surgeon. Therefore, word-of-mouth accounts of discomfort may have contributed to the relatively flat rate of growth of vasectomy during the past 10 years compared to tubal ligation.

Hematoma is the most common and uncomfortable complication of conventional vasectomy, with an average incidence of 2% and a range of 1 to 29%.<sup>2</sup> The no-scalpel method we describe is associated with a much lower rate of hematoma. Because the skin and vas sheath are punctured and the opening is then dilated, blood vessels are more likely to be pushed aside rather than cut. In this respect the no-scalpel procedure for vasectomy is analogous to percutaneous nephrolithotomy, where a small tract is established and dilated as compared to open stone surgery. Infection following incisional vasectomy is surprisingly common with an average rate of 3.4%<sup>2</sup> but several series report rates from 12 to 38%.<sup>3-5</sup> The incidence of infection with the no-scalpel method is substantially lower than that reported after conventional vasectomy.

The majority of 38 United States surgeons reporting to the Association for Voluntary Surgical Contraception noted reduced operative time, less bleeding, and less intraoperative and postoperative pain for their patients when they changed from an incisional to the no-scalpel technique. The no-scalpel technique was compared with a small single incision technique in a recent controlled study involving 1,203 men and 28 surgeons. The average no-scalpel vasectomy was performed in about 40% less time. The complication rate was 0.4 of 100 for the no-scalpel vasectomies and 3.1 of 100 for the incisional procedures.<sup>6</sup>

Like any new technique requiring new instruments and skills, the no-scalpel vasectomy may be difficult to learn. We have found that even experienced vasectomists require hands-on training and 15 to 20 procedures to develop proficiency. The no-scalpel method of gaining access to the vas deferens appears to be associated with fewer complications and less discomfort than conventional methods of exposing the vas. Its use helps to reduce fear of surgical injury and may serve to enhance the

popularity of vasectomy for permanent contraception.

Dr. Shihua Li provided the drawings, Dr. Arnold Belker reviewed the article, and Ms. Jean Schweis and the Population Council staff assisted in preparation of the manuscript.

#### REFERENCES

1. Li, S.-Q.: Vasal Sterilization Techniques: Teaching Material for the National Standard Workshop, Chongqing, People's Republic of China: Scientific and Technical Literature Press, p. 176, 1988.
2. Kendrick, J. S., Gonzales, B., Huber, D. H., Grubb, G. S. and Rubin, G. L.: Complications of vasectomies in the United States. *J. Family Pract.*, **25**: 245, 1987.
3. Appell, R. A. and Evans, P. R.: Vasectomy: etiology of infectious complications. *Fertil. Steril.*, **33**: 52, 1980.
4. Randall, P. E., Ganguli, L. and Marcuson, R. W.: Wound infection following vasectomy. *Brit. J. Urol.*, **55**: 564, 1983.
5. Randall, P. E., Ganguli, L. A., Keaney, M. G. L. and Marcuson, R. W.: Prevention of wound infection following vasectomy. *Brit. J. Urol.*, **57**: 227, 1985.
6. Nirapathpongporn, A., Huber, D. H. and Krieger, J. N.: No-scalpel vasectomy at the King's birthday vasectomy festival. *Lancet*, **335**: 894, 1990.



## NO-SCALPEL, NO-NEEDLE VASECTOMY

MARA A. MONOSKI, PHILIP S. LI, NEIL BAUM, AND MARC GOLDSTEIN

Vasectomy is the safest and most dependable method of permanent contraception available to men today. More than 500,000 vasectomies are performed in the United States and more than 55,000 in Canada each year. Of American married couples, 7% to 10% choose vasectomy as their form of birth control. This has made vasectomy the most common urologic procedure in North America.<sup>1-3</sup>

Although vasectomy is a safe and simple procedure for those who are well-trained, it can be technically challenging. Most contemporary surgeons and urologists have never been formally educated on how to perform a conventional vasectomy through a 2 to 3-cm incision or the newer no-scalpel vasectomy made through a 2 to 3-mm puncture wound on the scrotum. Many are forced to learn the procedure by trial and error during or after their residency training. Therefore, many urologists develop their own techniques that stray from more superior methods that have fewer complications and lower failure rates and may be accomplished with little or no pain. Kendrick and associates<sup>4</sup> illustrated how vasectomy performed by inexperienced hands leads to an increased incidence of complications such as bleeding, hematoma and infection.

We discuss the no-scalpel vasectomy and no-needle vasectomy, a unique and nearly painless technique for anesthetizing the scrotal skin and vas. Using a jet injector (MadaJet, Mada Medical Products, Carlstadt, NJ), the anesthetic solution is sprayed through the skin and around the vas using a high-pressure injector that patients have described as a "gentle snap of a rubber band" against

the scrotal skin.<sup>1,5</sup> The no-needle jet injection is a simple, effective, and safe technique that delivers excellent local anesthesia for vasectomy with high patient satisfaction. We believe this technique may reduce men's fear of the pain associated with the needle puncture involved in vasectomy and, in conjunction with the no-scalpel vasectomy, will likely enhance the popularity of vasectomy worldwide.

## HISTORY

In 1974, Dr. Shunqiang Li developed the no-scalpel vasectomy in China. Goldstein *et al.*<sup>6</sup> performed the first no-scalpel vasectomy in the United States in 1985 and published their experience using this technique in 1991. Since then, millions of men have undergone no-scalpel vasectomy in the United States and Canada. No-scalpel vasectomy has become the technique of choice for surgeons in North America.<sup>2</sup> It has also been popularized worldwide because of its minimally invasive approach, which reduces the incision size, procedure time, pain, bleeding, and post-operative complications compared with conventional scalpel vasectomy.<sup>2,3,6-11</sup> Since 1975, more than 15 million men have undergone no-scalpel vasectomy with a 10-fold reduction in complications compared with standard vasectomy.<sup>9</sup>

## INDICATIONS AND CONTRAINDICATIONS

It must first be determined whether vasectomy is an appropriate option for the patient. Information regarding the patient's age, reason for vasectomy, and relationship status should be documented. It is important to discuss with the patient alternative methods of contraception, risks of the procedure, which include failure, and possible complications such as bleeding and infection. The physician must ensure that the patient considers the procedure permanent and have him sign an informed consent form before undergoing vasectomy.<sup>3,12,13</sup> Men should also be encouraged to discuss this decision with their partner.

On physical examination, the presence of bilateral vas deferens should be assessed. The testes should be examined for any masses, because men seeking vasectomies are in the age range for testic-

From the Department of Urology and Center for Male Reproductive Medicine and Microsurgery, Cornell Institute for Reproductive Medicine, Weill Medical College of Cornell University, New York Presbyterian Hospital of Columbia and Cornell, New York, New York; Department of Urology, Tulane Medical School; and Department of Urology, Louisiana State University Medical School, New Orleans, Louisiana

Reprint requests: Marc Goldstein, M.D., Department of Urology, Weill Medical College of Cornell University, New York Presbyterian Hospital of Columbia and Cornell, Box 580, 525 East 68th Street, New York, NY 10021-4873. E-mail: mgoldst@med.cornell.edu

Submitted: November 10, 2005, accepted (with revisions): March 7, 2006



ular cancer. This is also an opportunity for doctors to show men how to perform a testicular self-examination.<sup>3</sup>

Certain conditions in which vasectomy should be delayed include active scrotal skin infections, epididymitis/orchitis, and balanitis because of the increased risk of postoperative infections. Men who have large varicoceles, hydroceles, or inguinal hernias may undergo vasectomy simultaneously with the repair of these other conditions. If an intrascrotal mass is present, a workup, including scrotal ultrasonography, must be performed before vasectomy to rule out malignancy. Caution should be used in men with a history of previous scrotal surgery and cryptorchidism, because it can be very difficult to locate the vas, making no-scalpel access more difficult. Men who have undergone prior varicocelectomy, especially with a non-artery-sparing or nonmicroscopic technique, are at risk of postvasectomy testicular atrophy if the testicular artery was ligated at varicocelectomy and they are dependent on the vasal artery for the blood supply to the testis. In these men, vasectomy should only be performed microsurgically, with preservation of the vasal (deferential) arteries and veins.

Situations in which vasectomy should not be done include men with bleeding diatheses because they are at risk for hematomas, which can grow to frightening size. Young men or men who are not in permanent relationships should consider other forms of birth control.

## ANESTHESIA

Until recently, anesthesia for vasectomy was administered into the scrotal skin and vas with a needle. However, the initial needle puncture is commonly the most anxiety-provoking aspect of the procedure for the patient. Now, a new and virtually painless application of anesthesia has been introduced that has revolutionized performance of vasectomy.<sup>1,14</sup> The purpose of no-needle jet injection, also called no-needle vasectomy, is to simplify the application of anesthesia for vasectomy, allay the fear of needles, and make vasectomy less painful.

### NEEDLE INJECTION

The first steps are to shave the scrotum, secure the penis against the patient's lower abdomen, and prepare the surgical area with Betadine. The next step involves bringing one vas to the scrotal surface at the median raphe using the three-finger technique to stabilize the vas (Fig. 1A).

For right-handed physicians, the left thumb is placed on the median raphe halfway between the base of the penis and the superior aspect of the testes. The left middle finger finds the vas on its posterior surface and brings it up to the median

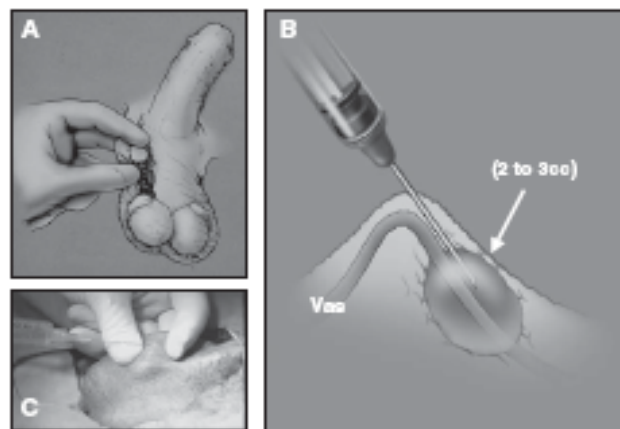


FIGURE 1. (A) Three-finger technique to isolate vas from vessels in spermatic cord. (B) Local vasal nerve block: raise wheal at skin surface, inject 2 to 3 mL of anesthetic solution along vas approximately 2 to 3 cm proximal to vasectomy site. (C) Needle injection of anesthesia using three-finger technique. Parts A and B were modified, with permission, from Weiss RS, and Li PS: No-needle jet anesthetic technique for no-scalpel vasectomy. *J Urol* 173(5): 1677-1680, 2005.

raphe so that it is caught between the thumb and middle finger (isolating it away from the rest of the testicular vessels in the spermatic cord). The index finger is then placed on the anterior surface of the vas proximal to where the other two fingers have the vas secured.

The standard anesthesia technique for no-scalpel vasectomy is a local vasal nerve block using a needle injection with 1% to 2% lidocaine without epinephrine (Fig. 1B,C). Initially, a wheal is raised at the skin surface. Then, the needle is advanced deeply and proximally along the perivascular sheath while injecting 2 to 3 mL of anesthetic solution. We suggest a single injection instead of multiple injections to reduce the risk of injury to the testicular vessels and subsequent hematoma.<sup>1,6,15</sup>

### NO-NEEDLE JET INJECTION (NO-NEEDLE VASECTOMY)

The jet injection technique uses an instrument that generates a high-pressure spray that forces anesthetic solution through the skin, vas, and surrounding vasal tissues providing complete anesthetic block of the vas (Fig. 2A). It provides near perfect, painless anesthesia, almost never requiring application of additional anesthetic.<sup>1,5</sup> Currently, MadaJet (US \$568 to \$662/set) is the brand used by our institution to perform no-needle vasectomy. Numerous jet injectors are available that are used in other fields of medicine. Some of these include the Syrijet Mark II (US \$1649/set, Keystone Industries, Cherry Hill, NJ) and the French-made DermoJet (US \$550/set, Akra Dermojet, Pau, France). The Syrijet Mark II is primarily used by

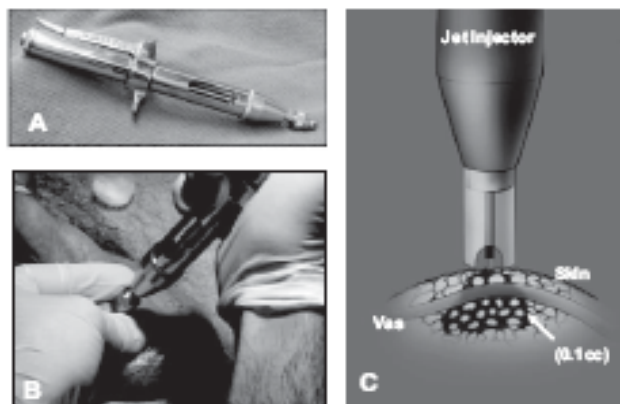


FIGURE 2. (A) Jet injector. (B) Jet injection of anesthesia along median raphe using three-finger technique. (C) Jet injection dispersion pattern. Part C was modified, with permission, from Weiss RS, and Li PS: No-needle jet anesthetic technique for no-scalpel vasectomy. *J Urol* 173(5): 1677–1680, 2005.

dentists and requires a special anesthetic cartridge. Currently, MadaJet is the most reliable and appropriate for vasectomy.

No-needle jet injection has multiple advantages.<sup>1</sup> It is less traumatic to the tissues, uses only one tenth the volume of anesthetic solution (approximately 0.1 mL/spray), and has a much more profound and faster onset of action (seconds versus minutes). The incidence of hematoma using jet injection is very low and, in experienced hands, can be negligible.<sup>1,16</sup> This was illustrated by Weiss *et al.*<sup>14</sup> who had no hematomas develop after performing no-needle vasectomy on 1391 patients in 2004.

All the components of the jet injector are autoclavable for proper sterilization. Approximately 4 to 5 mL of anesthetic solution is used to load the filling chamber. The jet injector assembly is affixed to the filling chamber. A spacer with a notch at the tip of the jet injector fits over the vas and allows enough distance for the spray of anesthesia to spread out in a cone-shaped distribution before and just after penetrating the skin. The instrument is then primed by pumping the lever and firing several times to ensure it is functioning properly.

The patient is positioned and shaved as described previously. The right vas is grasped using the three-finger technique and brought to the surface of the scrotal skin at the median raphe. It is important to wear a finger protector over the middle finger of the nondominant hand behind the vas to prevent accidental injection of anesthesia through the scrotum into the practitioner's finger. This will only occur if the vas is not trapped in the groove of the injector. Normally, if the injection is properly directed into the vas wall, it will not penetrate through the posterior scrotal wall.

The skin over the median raphe only has to be swabbed with an alcohol pad before the administration of anesthesia. The groove in the spacer on the tip of the jet injector is placed firmly over the right vas on the median raphe at the junction of the upper one third and lower two thirds of the scrotum (Fig. 2B). Three sprays of anesthesia are applied along the left lateral aspect of the median raphe approximately 4 to 5 mm apart. Then, the left vas is brought to the same position at the median raphe, except that three injections are applied to the right lateral aspect of the median raphe adjacent to the previous injections. This crossed anesthesia along the median raphe gives a wider anesthetic field to the skin and underlying tissues and ensures patient comfort throughout the skin puncture and tissue manipulation during no-scalpel vasectomy.

The jet injection is very effective because the anesthesia solution disperses in an inverted cone-shape distribution, affecting all the tissues to a depth of 4 to 4.5 mm from the skin surface (Fig. 2C). The anesthetic solution is quickly absorbed by the tissue around the vas, with much less trauma and pain than after needle injection. No skin wheal or local edema is present at the injection site, making no-scalpel vasectomy easier to perform. The injection sites are recognized by small blanched discolorations of the skin.

Studies have been performed analyzing the pain scores involved in the application of anesthesia for vasectomy and the vasectomy itself. Using a visual analog scale, Weiss and Li<sup>1</sup> found that the average pain score for the jet injection of anesthesia was 1.71 of 10 (range 1 to 7.40, median 1.3). The average visual analog scale pain score for the vasectomy that was subsequently performed after jet injection was 0.66 of 10 (range 0 to 6.60, median 0.2).<sup>1</sup>

The area is then prepared with Betadine and draped in standard surgical fashion. At this time, the tip of the jet injector should be soaked in a disinfectant solution (MadaCide is recommended by Mada Medical Products) to adequately sterilize it before its use on the next patient.

## SURGICAL PROCEDURE

Vasectomy consists of two components: access to the vas and vasal occlusion. It is important to understand that the no-scalpel vasectomy is one method for gaining access to the vas and conventional vasectomy is another option. Once the vas is delivered out of the scrotum, the method of vasal occlusion can vary depending on physician preference.

### ACCESS TO THE VAS

Conventional vasectomy involves making either bilateral transverse incisions high on the scrotum



or the preferred single vertical incision on the median raphe to expose the vas. At this point, any of the many techniques for vasal occlusion can be used. Once this has been accomplished, the scrotal incisions can either be left open if they are less than 1 cm long or closed with a few interrupted absorbable sutures.

The no-scalpel vasectomy has been proved a superior method of gaining access to the vas compared with conventional vasectomy. It is an elegant technique for exposing the vas through a tiny puncture wound 2 to 3 mm in length, with negligible pain and trauma to the surrounding tissues.<sup>3</sup> Not only can it be performed faster, but the incidence of hematomas and infections is decreased and the postoperative recovery time is shorter.<sup>17</sup>

The first step is to fix one of the vas against the scrotal skin at the median raphe using the three-finger technique. A ring-tipped fixation clamp is used to grasp the vas through the skin. One blade of a sharp, pointed, curved mosquito hemostat (dissecting forceps) is used to puncture through the scrotal skin for 5 mm or to the lumen of the vas. The instrument is removed, and both tips of the dissecting forceps are reinserted into the puncture site and spread transversely across the vas to strip the skin and vasal sheath away from the bare vas.

After spreading the tissue on top of the vas adequately, one blade of the dissecting forceps is used to pierce the vas to the lumen. The blade inside the vas lumen is rotated 180° and then the vas is lifted up and out through the scrotal skin, at the same time releasing the ring clamp. This will allow the vas to be pulled up and out of the scrotal skin. The exposed vas is regripped with the ring clamp to keep it from falling back into the scrotum. Approximately 1 cm of the vas is dissected free from its sheath longitudinally with the dissecting forceps. The vas is occluded using any of the techniques described below.

The contralateral vas is brought through the same puncture site and is occluded using an identical approach. At the end of the procedure, it is necessary to inspect the ends of the vas and the wound for any bleeding to prevent hematoma formation. It is seldom necessary to close the puncture wound with sutures. It is merely compressed for 1 minute and then covered with antibiotic ointment.

#### VAS OCCLUSION

Numerous techniques for vasal occlusion exist and are used throughout the world. These include ligation of the vas with either suture or clips, excision of a segment of vas of various lengths, folding back the end of the vas onto itself, fascial interposition between the cut ends of the vas, and cautery of the lumen of the vas (thermal or electric).<sup>10</sup>

These techniques have been used alone and in various combinations. However, it has been difficult to determine which method or combination of methods is truly most effective to prevent recanalization and vasectomy failure because of the heterogeneity of study design, surgical technique used, and assessment of results.<sup>10</sup>

The method used most often worldwide is suture ligation and excision. This is especially true for economically challenged areas, because it is the simplest and quickest technique to perform, with the least amount of materials needed.<sup>18</sup> However, this technique used alone is the least effective and has a failure rate of approximately 1% to 5%.<sup>2</sup> This could be because of necrosis at the ends of the vas distal to the ligature, allowing recanalization to occur more easily. Some studies have shown that the addition of fascial interposition, in which the vasal sheath is pulled back over the cut end of the vas and secured in place, increases the effectiveness of vasal occlusion by ligation and excision.<sup>10</sup> Nevertheless, fascial interposition is a more complicated technique and increases the time needed to perform vasectomy.

The most effective technique is thought to be cautery combined with fascial interposition. Data collected from multiple studies have shown a failure rate of 0% to 1.2%.<sup>10</sup> However, it has been debated whether thermal versus electric cautery is more effective. Several studies have suggested thermal cautery to be superior. One study in particular showed histologic proof of the ability of thermal cautery over electric cautery to occlude the vas, as evidenced by fewer cases of vasitis nodosa and spermatic granuloma.<sup>19</sup> Even with this information, the question remains whether cautery alone is better than ligation and excision.

A recent survey of vasectomists in the United States looked at the use of different vasal occlusion methods specifically in America. The survey found that 70% used cautery to occlude the vas during vasectomy. The second most popular occlusion technique is ligation, used by approximately 60% of practitioners. Additionally, about one quarter of all vasectomists apply metal clips to the vas.<sup>20</sup>

#### RESULTS AND COMPLICATIONS

The most common complications associated with vasectomy are hematoma formation and infection. On average, 2% of conventional vasectomies are complicated by the formation of a hematoma postoperatively.<sup>4</sup> With the no-scalpel technique, the incidence of hematoma is less than 0.5%. Infection is a relatively rare occurrence when vasectomy is performed under sterile conditions. However, when it



does occur, it is usually associated with an underlying hematoma.<sup>3</sup> It is well documented that that the experience of the physician is the most important factor in the incidence of complications encountered after vasectomy.<sup>4</sup>

Sperm granulomas form when sperm leak from the testicular side of the vas, leading to an inflammatory reaction. Some studies have shown that the formation of sperm granulomas can have a positive effect on patency rates in vasectomy reversals by decreasing the pressure-induced damage on the epididymis.<sup>21</sup> However, sperm granulomas can lead to unacceptably high recanalization and vasectomy failure rates.<sup>3</sup>

Most pressure produced on the testicular side of the vas after occlusion is transmitted to the epididymis and efferent ductules, but not the seminiferous tubules. Minimal damage more distally in the system has been shown by electron microscopic studies of the testis, demonstrating areas of basal lamina thickening and spermatogenesis disruption.<sup>22</sup> However, Leydig cells remained normal, with no injury to their structure or function.<sup>3</sup>

Several possible long-term effects associated with vasectomy include chronic testicular/epididymal pain, testicular dysfunction, vasitis nodosa, and chronic epididymal obstruction.<sup>2</sup> Approximately 1 in 1000 men will experience chronic testicular/epididymal pain postoperatively.<sup>23</sup> Possible treatments for this bothersome complication include vasectomy reversal, open-ended vasectomy, or even total epididymovasectomy.

Systemic effects such as the development of anti-sperm antibodies can occur secondary to breakdown of the blood-testicular barrier. It has been postulated that the formation of immune complexes can occur, ultimately leading to atherosclerosis. However, multiple studies have failed to show the formation of these immune complexes or their deposition in vasectomized men.<sup>2,3</sup>

There has also been a concern that vasectomy may increase the incidence of prostate and testicular cancer. This initial perception was probably a result of a selection bias because men undergoing vasectomy were seeing a urologist and were more likely to be screened, and therefore diagnosed, with urologic cancer. Many studies have shown this to be false. Men can be comfortable that vasectomy will not put them at a greater risk of genitourinary cancer.<sup>3</sup>

Before a man can start having unprotected sex after vasectomy, he must be completely azoospermic. At least one to two semen analyses 4 to 6 weeks apart should be obtained 12 weeks after surgery. A repeat vasectomy should be performed if any motile sperm are found in the ejaculate 3 months after surgery.<sup>2</sup>

## OPPORTUNITIES AND MARKETING POTENTIAL

Although no-scalpel vasectomy was introduced to the United States more than 20 years ago, many urologists still do not know how to perform this technique properly. Now, with the addition of no-needle vasectomy for the application of local anesthesia, there is a wonderful opportunity to provide men with a virtually painless and extremely effective form of permanent contraception.

Vasectomy is an excellent opportunity for additional revenue for any urologist. Physicians can charge approximately U.S. \$650 per vasectomy, which is commonly a cash-pay procedure compared with the U.S. \$100 billed for a new level 3 patient visit. Vasectomy takes only 10 to 20 minutes to perform, resulting in a tremendous revenue/time ratio. If a physician can add five vasectomies a month by increased exposure on the Internet, this translates into a profit of U.S. \$3000 to 4500/mo or US \$40,000 to 55,000 annually. Another advantage to performing more vasectomy procedures is that urologists can increase their practice by additional patients and referrals from the patients' friends and family with other urologic conditions.

**ACKNOWLEDGMENT.** To Drs. Ronald Weiss and Doug Stein in pioneering the use and acceptance of no-scalpel and no-needle vasectomy and for sharing their experiences with us and to Dr. Ronald Weiss for allowing us to use some of his surgical images in Figures 1 and 2.

## REFERENCES

1. Weiss RS, and Li PS: No-needle jet anesthetic technique for no-scalpel vasectomy. *J Urol* 173: 1677-1680, 2005.
2. Goldstein M: Surgical management of male infertility and other scrotal disorders, in Walsh PC, Retik AB, Vaughan ED, et al (Eds): *Campbell's Urology*, 8th ed. New York, WB Saunders, 2002, pp 1541-1547.
3. Schlegel PN, and Goldstein M: Vasectomy, in Goldstein M (Ed): *Surgery of Male Infertility*. New York, WB Saunders, 1995, pp 35-45.
4. Kendrick J, Gonzales B, Huber D, et al: Complications of vasectomies in the United States. *J Fam Pract* 25: 245-248, 1987.
5. Wilson CL: No-needle anesthetic for no-scalpel vasectomy. *Am Fam Physician* 63: 1295, 2001.
6. Li S, Goldstein M, Zhu J, et al: The no-scalpel vasectomy. *J Urol* 145: 341-344, 1991.
7. Viladoms JM, and Li PS: Vasectomy sin Bisturi. *Arch Esp Urol* 47: 695-701, 1994.
8. Kaza RM, Singh I, Singhal S, et al: An evaluation of the no-scalpel vasectomy technique. *BJU Int* 83: 283-284, 1999.
9. Nirathpongpor A, Huber D, and Krieger JN: No-scalpel vasectomy at the King's birthday vasectomy festival. *Lancet* 335: 894-895, 1990.
10. Labrecque M, Defresne C, Barone MA, et al: Vasectomy surgical techniques: a systematic review. *BMC Med* 2: 21-33, 2004.
11. Skiver M, Skovsgaard F, and Miskowiak J: Conventional or Li vasectomy: a questionnaire study. *BJU Int* 79: 596-598, 1997.

12. Haws JM, and Feigin J: Vasectomy counseling. *Am Fam Physician* 52: 1395–1399, 1995.
13. Schmidt SS: Vasectomy. *Urol Clin North Am* 14: 149–154, 1987.
14. Weiss RS, Li PS, and Goldstein M: No-needle jet anesthetic technique for the no-scalpel vasectomy (abstract). *Can J Urol* 12: 2664, 2005.
15. Li PS, Li SQ, Schlegel PN, *et al*: External spermatic sheath injection for vasal nerve block. *Urology* 39: 173–176, 1992.
16. Weiss RS, and Li PS: No-needle jet anesthetic technique for the no-scalpel vasectomy (abstract). *J Urol* 173: 367–368, 2005.
17. Sokal D, McMullen S, Gates D, *et al*: The male sterilization investigator team: a comparative study of the no scalpel and standard incision approaches to vasectomy in 5 countries. *J Urol* 162: 1621–1625, 1999.
18. Labrecque M, Pile J, Sokal D, *et al*: Vasectomy surgical techniques in South and South East Asia. *BMC Urol* 5: 10–19, 2005.
19. Schmidt SS, and Minckler TM: The vas after vasectomy: comparison of cauterization methods. *Urology* 40: 468–470, 1992.
20. Haws JM, Morgan GT, Pollack AE, *et al*: Clinical aspects of vasectomies performed in the United States in 1995. *Urology* 52: 685–691, 1998.
21. Silber SJ: Sperm granulomas and reversibility of vasectomy. *Lancet* 2: 588–589, 1977.
22. Jarow JP, Budin RE, Dym M, *et al*: Quantitative pathological changes in the human testis after vasectomy. *N Engl J Med* 313: 1252–1256, 1985.
23. McConaghy P, Paxton LD, and Loughlin V: Chronic testicular pain following vasectomy. *Br J Urol* 77: 328, 1996.

MARC GOLDSTEIN, MD

## No-scalpel vasectomy: A kinder, gentler approach

Compared to the traditional technique, no-scalpel vasectomy produces less tissue trauma, a lower risk of infection, and minimal bleeding. It can even turn men who feared vasectomy into advocates for the procedure.

**N**o-scalpel vasectomy (NSV) was developed in China in 1974 and introduced to the United States in 1985. In a traditional vasectomy, the surgeon makes one or two incisions to gain access to the vas deferens; in the no-scalpel method, a small puncture is all that is required. Primary care physicians are finding this safe and minimally invasive option appropriate when counseling couples about contraception—especially when the man excessively fears a knife being applied to his genitals.

Over the past two decades, the number of American couples choosing vasectomy as their method of contraception has risen. Nearly half a million men opt for the method each year, making it the third most popular form of contraception after female sterilization and oral contraception.\*

When considering vasectomy as an option, couples are relieved to learn that even the traditionally performed procedure is associated with a lower incidence of complications

and death than tubal ligation. Nevertheless, men who are considering vasectomy often have a psychological aversion and are apprehensive about physical discomfort during and after the procedure.

When a patient learns that the no-scalpel method is safer and easier than the more invasive procedure, most of these fears are allayed. Whichever vasectomy technique is employed, the procedure is not without controversy (see "Controversies and myths about vasectomy," page 56).

### THE SURGICAL TECHNIQUE

NSV was developed in 1974 at the Chongqing Family Planning Scientific Research Institute in China's Sichuan Province. This method of gaining access to the vas deferens has been widely adopted in Sichuan, where more than 9 million men have undergone the procedure.

In 1985, an international team of experts put together by the Association for Voluntary Surgical Contraception (AVSC) and the World Health Organization visited China to learn alternative vasectomy techniques. Today, urologists throughout the world have been trained to perform the NSV technique described here, and upwards of 6,000 procedures have been performed in the United

\**Population Reports*. Population Information Program. Baltimore, The Johns Hopkins University Press, March 1992, p 21.

#### ARTICLE CONSULTANT

**MARC GOLDSTEIN, MD** professor of urology and director, center for male reproductive medicine and microsurgery, department of urology, James Buchanan Brady Foundation, New York Hospital-Cornell Medical Center, New York City



States. NSV is taught to primary care physicians through the American Academy of Family Physicians (AAFP) and other professional organizations.

Performing NSV requires training and hands-on experience. But even primary care physicians who don't perform vasectomies need to understand the no-scalpel method so that their patients who undergo the procedure can receive appropriate referrals and follow-up care.

### Preparation

Clip or shave the patient's scrotal skin and retract the penis upward onto the abdomen by placing a rubber band noose or stretchy adhesive tape around the glans and securing it with a clamp to the patient's gown. Prep the skin with a warm antiseptic solution. Because a relaxed scrotum facilitates the procedure, avoid cold antiseptic solutions, cold procedure rooms, and cold hands. Oral sedation with 10 mg of diazepam (Valium)

### Controversies and myths about vasectomy

Despite the proven efficacy of vasectomy as a method of contraception, unresolved issues and misunderstandings persist. The castration myth is alive and well among patients, and researchers continue to study the effects of vasectomy on hormone production and atherosclerosis, the risk of prostate and testicular cancer, and HIV transmission. Ongoing studies are examining the significance of antisperm immunity and the effects of protamine administration after cardiac surgery in vasectomized men.

A major controversy is the possible link between vasectomy and prostate cancer, the second leading cause of cancer deaths in men. Two recent studies have found an increased risk of prostate cancer in men who had had a vasectomy 20 years previously.\* But two other large-scale cohort studies that evaluated men from a wide range of socioeconomic strata did not find a link between vasectomy and prostate cancer.† In addition, a study of vasectomy sequelae found the procedure to have an excellent record of effectiveness and safety.‡

The most likely explanation for the increased *diagnosis of prostate cancer in vasectomized men* is that those men are more likely to visit a urologist and therefore more likely to have cancer diagnosed earlier. Further, men who choose to undergo vasectomy may be more likely to seek health care, increasing the possibility of prostate cancer detection. In 1993, a multidisciplinary National Institutes of Health (NIH) panel concluded that epidemiologic associations are

weak. It recommended no change in clinical or public health practice and said that screening for prostate cancer should not be any different for vasectomized men.\*

A cohort study of more than 73,000 men in Denmark found no increased risk of testicular cancer in vasectomized men and showed that vasectomy neither induces testicular tumorigenesis nor accelerates the growth or diagnosis of preexisting testicular neoplasms.†

One of the most publicized myths surrounding vasectomy is the so-called castration effect. A decline in feelings of masculinity is not only rare after vasectomy, but vasectomized men have been reported to enjoy greater sexual satisfaction. This may be because they no longer have to worry about the prospect of unwanted pregnancy.

Vasectomy has a statistically significant, but physiologically insignificant, effect upon hormone production. The serum testosterone level increases slightly due to absorption of small amounts of testosterone in the semen. No increase has been shown in the incidence of atherosclerosis or heart disease in vasectomized men. Antisperm antibodies have been found following vasectomy in a high percentage of men in whom such antibodies were not detected previously, but the implications of this are unclear.

Men seeking vasectomy should be informed of the risks and be counseled about the controversies. The American Urological Association (AUA) now recommends annual digital rectal examination and serum prostate-specific antigen assay for all men 50-75 years old and men who are at significant risk for prostate cancer. This includes African-American men and those with a family history of the disease. According to the AUA, the NIH, and the American Cancer Society, vasectomized men need no specialized preventive care.

\*Giovannucci E, Ascherio A, Rimm EB, et al: A prospective cohort study of vasectomy and prostate cancer in US men. *JAMA* 1993;269:873-877.

Giovannucci E, Tosteson TD, Speizer FE, et al: A retrospective cohort study of vasectomy and prostate cancer in US men. *JAMA* 1993;269:878-882.

†Nienhuis H, Goldacre M, Seagroatt V, et al: Incidence of disease after vasectomy: A record linkage retrospective cohort study. *BMJ* 1992;304:743-746.

Sidney S, Quesenberry CP, Sadler MC, et al: Vasectomy and the risk of prostate cancer in a cohort of multiphasic health-checkup examinees: Second report. *Cancer Causes Control* 1991;2:113-116.

‡Schuman LM, Coulson AH, Mandel JS, et al: Health status of American men: A study of post-vasectomy sequelae. *J Clin Epidemiol* 1993;46:697-958.

\*Healy B: From the National Institutes of Health: Does vasectomy cause prostate cancer? *JAMA* 1993;269:2620.

†Moller H, Knudsen LB, Lynge E: Risk of testicular cancer after vasectomy: Cohort study of over 73,000 men. *BMJ* 1994;309:295-299.

30-60 minutes before the procedure relaxes both patient and scrotum. Alternatively, intravenous midazolam HCl (Versed), 2 mg in 6 mL of normal saline, can provide faster sedation.

#### Local anesthesia

Standing on the patient's right side, use your right hand to separate the vas deferens from internal spermatic vessels and manipulate it to a superficial position under the median raphe, at the junction of the middle and upper third of the scrotum. With the left hand, firmly trap the right vas over the middle finger and under the thumb and index finger (see Figure 1). This is the three-finger isolation technique.

Raise a superficial skin wheal with 2% lidocaine HCl (Xylocaine HCl) without epinephrine, using a 1-inch or 1.5-inch 25-27-gauge needle. Advance the needle in the perivasal sheath toward the external inguinal ring, and inject 3-5 mL of lidocaine, effecting a high vasal nerve block away from the actual vasectomy site (see Figure 2). Fix the left vas deferens under the skin wheal with the same three-finger technique, and anesthetize it. Then pinch the skin wheal to reduce local edema.

#### Fixation of the vas

Two specialized instruments designed in China are used in NSV: an extracutaneous vas deferens fixation ring clamp and a dissecting clamp modified from a curved mosquito hemostat (see Figure 3, page 58). After both vasa have been anesthetized, fix the right vas again under the site of the skin wheal with the left hand, using the three-finger method. Hold the fixation ring clamp, and press the open tips exactly perpendicularly onto the skin immediately overlying the midline of the vas (see Figure 4, page 58). Open

the clamp while exerting counterpressure downward, thus stretching the scrotal skin tight over the underlying vas.

Lock the ring clamp around the vas. The cantilevered feature of this clamp minimizes damage to the scrotal skin even when locked tightly. Holding the ring clamp near its tip in the left hand, elevate the entrapped vas. With the left index finger, press down to tighten the scrotal skin just beyond the tip of the clamp.

*Continued*

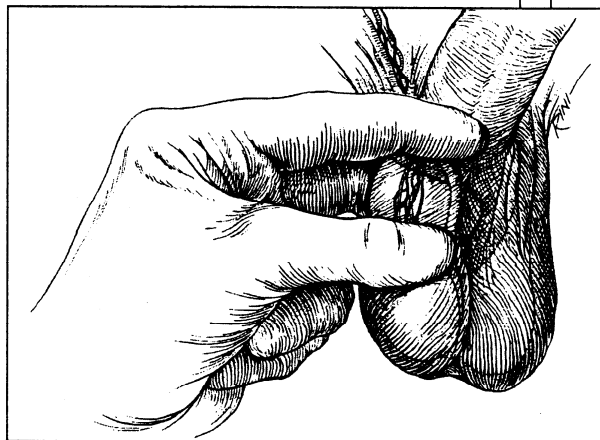


FIGURE 1: The three-finger isolation technique makes it easy to manipulate each vas to a superficial position at the median scrotal raphe.

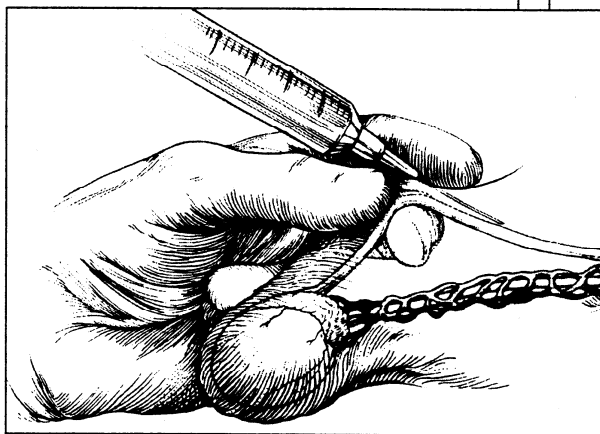


FIGURE 2: To avoid edema at the vasectomy site, perform a vasal nerve block away from the point of skin entry. The tip of the needle lies against the vas during the injection.

### Delivery of the vas

With the curved tips of the dissecting clamp facing downward, use the left blade of the opened clamp to pierce the scrotal skin, vas sheath, and vas wall at a point where the vas is most superficial and prominent (see Figure 5). The vas should be held exactly at its midline, and the angle between the tip of the left blade and the horizontal plane should be 45 degrees.

Withdraw the left blade of the dissecting clamp, close the instrument, and introduce both blades through the puncture hole at the same 45-degree angle. Open the blades of the dissecting clamp, spreading all layers down to the bare vas wall. Using the right blade of the clamp, skewer the bare vas at a 45-degree angle, and rotate the clamp 180 degrees until the blades are pointing upward (see Figure 6, page 60). To facilitate skewering the bare vas,

FIGURE 3: **Instruments** specialized for no-scalpel vasectomy include an extracutaneous vas deferens fixation ring clamp with a cantilevered design (a) and a dissecting forceps (b). The dissecting forceps is fashioned from a curved mosquito hemostat with its serrations ground off and its points sharpened.

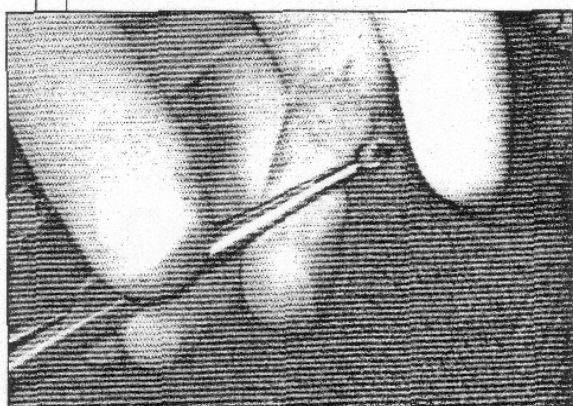
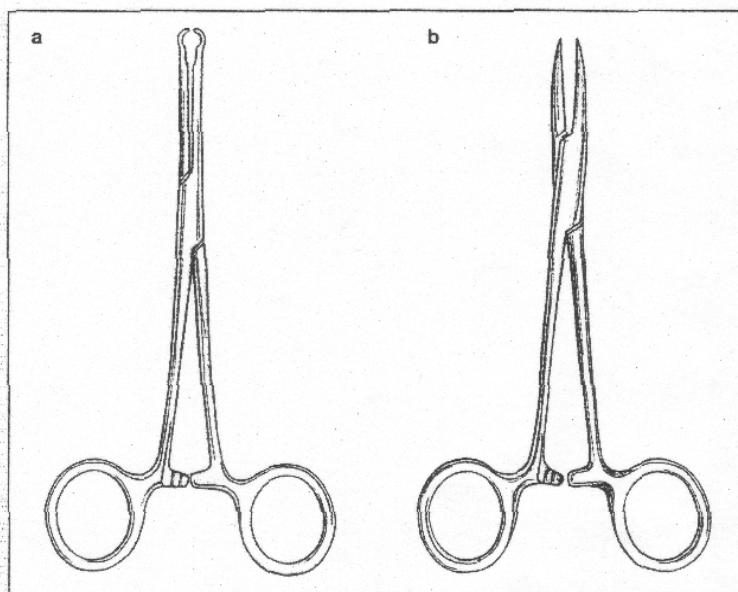


FIGURE 4: The vas is grasped extracutaneously with the ring clamp. Note the use of the left index finger to stretch the scrotal skin just beyond the tip of the clamp.

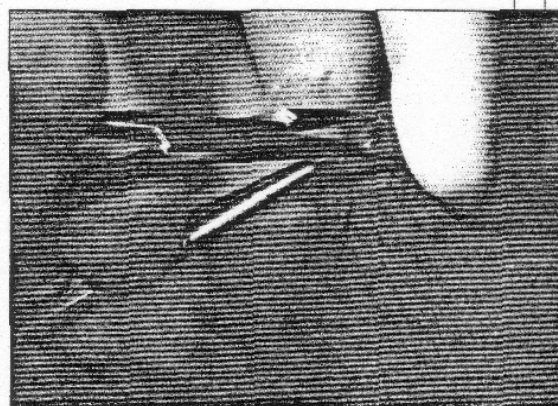


FIGURE 5: Percutaneous puncture of the vas is performed at a point of its maximal curvature, with the tips at a 45-degree angle to the horizontal plane.



alter the axis of the dissecting clamp by approximately 45 degrees with a simultaneous lateral movement.

As you begin to lift the vas through the puncture hole, release and reposition the ring clamp so it grasps the delivered vas. Then use the right blade of the dissecting clamp to pierce through an avascular plane under the apex of the loop between the bare vas and its vessels. Through this small window, gently strip the sheath and vasal vessels away from the vas, yielding a clean segment of vas approximately 2.0-2.5 cm long (see Figure 7, page 64). *Little or no bleeding should be encountered throughout the procedure.*

#### Occlusion of the vas

Cautery, sutures, or hemoclips can be used for vasal occlusion. With the ring clamp holding it, hemitranssect the bare vas at two

points flanking a 1-cm vas segment. If cautery is chosen, cauterize each vasal lumen for a distance of 1 cm. To effect a circumferential mucosal burn, rotate the cautery unit within the vasal lumen. (Overzealous electrocautery may lead to transmural burn and necrosis, predisposing to sperm leakage, granuloma formation, or recanalization.) Medium hemoclips or sutures can be applied to the cauterized vasal segments to prevent the leakage of sperm until the segments are sealed by fibrous plugs.

After clipping, completely transect the *testicular and prostatic ends of the vas*, and allow the vas segments to partially retract into the wound to check for bleeding. Fascial interposition of either vas segment can be accomplished by applying a hemoclip to the sheath immediately after the transected vas retracts.

*Continued*

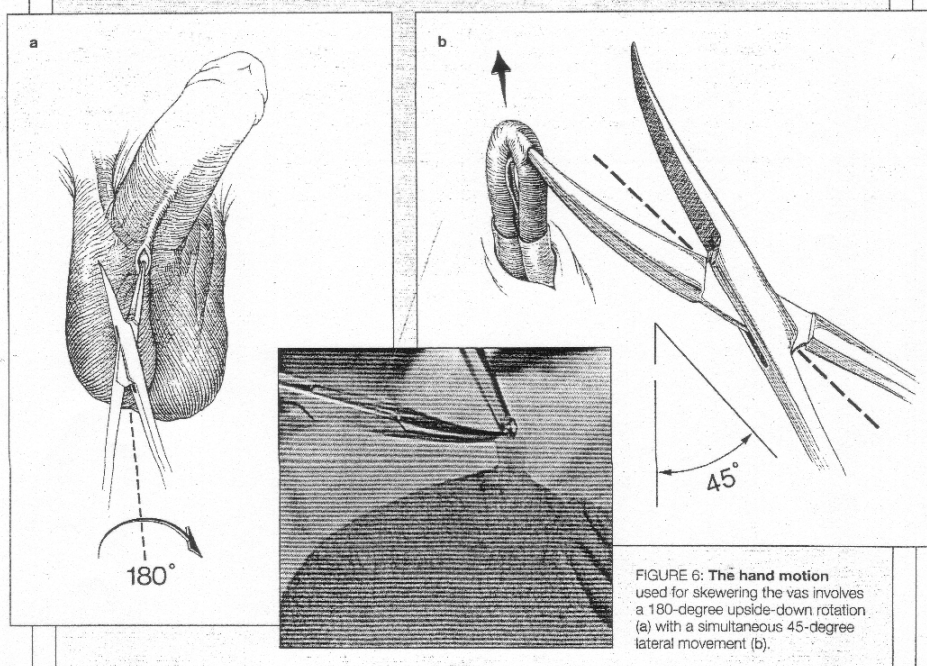


FIGURE 6: The hand motion used for skewering the vas involves a 180-degree upside-down rotation (a) with a simultaneous 45-degree lateral movement (b).

#### Completing the procedure

After occlusion, return the ends of the right vas to the scrotum. Fix the left vas directly under the puncture site, using the three-finger technique. If local edema renders fixation of the skin and underlying vas impossible, gently place the ring clamp through the puncture hole, and encircle the vas and its sheath without the overlying skin.

The rest of the procedure is identical to that described for the remaining side. After both vasa are occluded and returned to the scrotum, tightly pinch the puncture site for a minute and inspect it for bleeding. The puncture hole will have contracted and will be virtually invisible to the patient. Apply antibiotic ointment and a sterile dressing over the puncture site. The dressing should be held in place with a snug-fitting scrotal supporter. Instruct the patient to lie supine as much as possible for a day, applying intermittent ice packs for the first eight hours. The patient

may remove the scrotal dressing after 24-48 hours (for patient information, see "What you should know about vasectomy," page 74).

Heavy lifting and ejaculation should be proscribed during the week following vasectomy. Albeit rare, spontaneous recanalization is a possibility, regardless of the vasectomy method or occlusion technique. Men must be told to use contraception until a semen analysis is negative for sperm (see "Other approaches to the procedure").

#### RATING THE METHODS

The primary difference between NSV and conventional incisional vasectomy lies in the delivery of the vas deferens, so it is appropriate to compare complications related to this aspect alone. Other complications of vasectomy—recanalization, epididymitis, sperm granuloma—are related to occlusion and independent of the vas delivery technique.

Studies indicate that NSV has an extreme-

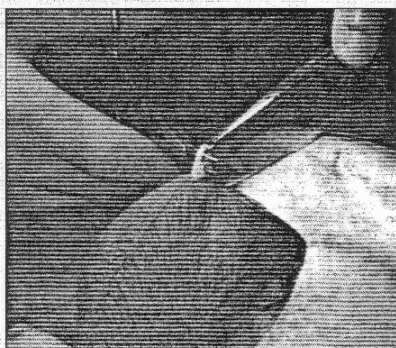
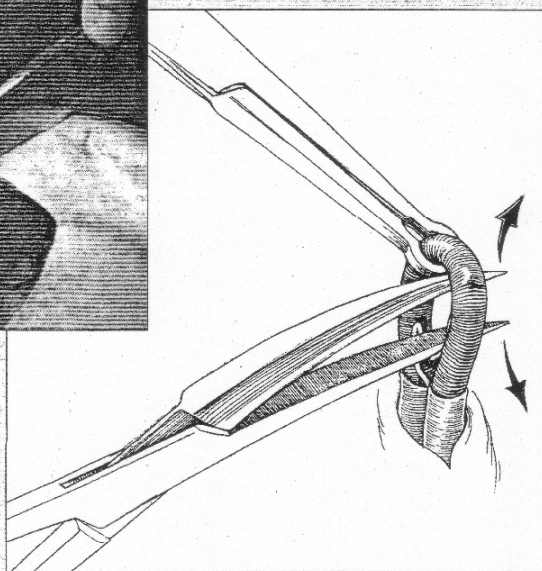


FIGURE 7: The **vasal vessels** are carefully stripped off the bare vas to yield a 2.0-2.5-cm clean segment. The vas is then occluded.



ly low incidence of infection and hematoma. Logically, the potential for infectious complications should be reduced by performing a technique through a small puncture wound that does not require suture closure and involves minimal dissection and tissue trauma. Sutures may create a portal of entry for perineal bacteria. In contrast, the small puncture used in NSV typically seals within 24 hours. In the absence of sutures, free

drainage can occur during this period. A prospective, randomized study in Thailand comparing the side effects of the two vasectomy techniques showed that of 523 men, 1.34% became infected and 1.72% developed hematoma or hemorrhage after the traditional incisional procedure.\* Of 680 men who underwent NSV, 0.15% became infected and

\*Nirapathpongporn A, Huber DH, Krieger JN: No-scalpel vasectomy at the King's birthday vasectomy festival. *Lancet* 1990;335:894-895.

## Other approaches to the procedure

As primary care physicians add no-scalpel vasectomy (NSV) to their schedule of office procedures, methods of anesthesia, occlusion, and counseling are evolving.

Ronald D. Reynolds, MD, a family physician in private practice near Cincinnati, is an advocate, practitioner, and teacher of NSV. He doesn't use the high perivascular block to anesthetize patients. "That makes it difficult for me to be sure where I'm placing the anesthetic," Dr. Reynolds says. "Instead, I raise a skin wheal at the three-finger isolation point, then advance the needle in the inguinal direction onto the vas and place anesthetic superiorly and on the sides."

Dr. Reynolds prefers a 50:50 mixture of 2% lidocaine HCl (Xylocaine HCl) and 0.5% bupivacaine HCl (Marcaine HCl, Sensorcaine), seeking immediate onset of action with lidocaine and extended action of up to six hours with bupivacaine. He uses about 1 mL for the skin and about 1.5 mL around each vas. "That way I inject reliable anesthesia, and I know where it's going. I've never had a problem with tissue distension."

Before the procedure, Dr. Reynolds gives oral diazepam (Valium), 10 mg, for relaxation, then amoxicillin/potassium clavulanate (Augmentin),\* 250 mg (based on the amoxicillin component), to prevent infection. Postoperatively, he prescribes salsalate (Disalcid),\* two 750-mg tablets bid for seven days, to minimize pain or swelling.

Dr. Reynolds sees a need to ensure adequate blood supply to the operative site. "Because the puncture is so small," he observes, "the skin often acts as a tourniquet to the vas loop, subjecting the vasal artery to a risk of inadvertent injury. If necessary, I further stretch the skin puncture with a curved hemostat until I see the artery pulsing so any bleeding can be perceived and fixed."

Dr. Reynolds' method for occlusion is red-hot wire cautery and suture closure of the sheath. "Once the loop is out, I tease the sheath off the prostatic side of the loop, using the dissecting forceps. I hold this layer in the tips of two fine mosquito hemostats. I herni-tran-

sect the vas, cauterize in both directions, and complete the transection. Using absorbable 5-0 polyglycolic acid (Vicryl) suture on a GI (taper) needle, I make a three-point triangulation of the sheath, pulling the most superficial sheath down onto the deep side of the sheath. The resultant purse string in the sheath completely covers the prostatic end."

Postoperative care includes two sperm counts. Sperm cannot live in the ampullary storage area for more than three weeks without replenishment, and it takes approximately 15 ejaculations to clear sperm out of the ampulla. Dr. Reynolds has patients submit a first semen sample a minimum of four weeks and 15 ejaculations after surgery. Another sample is tested in two weeks. "Only after two counts two weeks apart are zero," he explains, "do I consider the operation a success."

John L. Pfenninger, MD, also a family physician, founded the National Procedures Institute in Midland, Mich., five years ago and began using the no-scalpel technique three years ago. He does about 120 NSVs a year and has had a zero failure rate.

Men who approach the concept of vasectomy with fear often come away from NSV converted. Dr. Pfenninger relates this story: "One patient said, 'I want you to do the no-scalpel technique, but I want it done in the hospital because I faint all the time.' I said, 'But any doctor there will use a scalpel. I don't do vasectomies in the operating room.' We talked for 10 minutes or so, and finally I said, 'I'll tell you what. I'll bet you a 12-pack that we can do it in my office and that you won't faint and won't have any pain.' He took me up on it. I used diazepam 10 mg po one hour prior to surgery along with 800 mg of ibuprofen (Motrin, Rufen). Just before the procedure, we gave 0.5 mg of atropine sulfate."

"When he got off the table, he said, 'Doc, if you could do it to me, you could do it to anybody.' About eight weeks later I found a 12-pack of beer sitting next to a semen sample in my office."

Dr. Pfenninger points out that a good deal of psychology is involved in discussing the procedure with anxious patients. "A man's reaction is less apprehensive when you describe the puncture as an opening, rather than a scalpel incision."

\*Unlabeled use.



0.3% developed hematoma or hemorrhage.

A major advantage is that NSV markedly reduces the psychological barrier for many men, allowing them to consider surgery on their genitals. Since the procedure is safer and more cost-effective than tubal ligation, this factor is significant.

In addition, NSV requires less operating time. In the Thailand study, a team of physicians using NSV performed an average of 57 procedures in the same time it took another team to perform 33 vasectomies with the conventional technique.\* Similarly, in a series carried out in the United States, a 40% reduction in operating time was reported: 5-11 min-

utes for NSV versus approximately 20-30 minutes for the traditional procedure.\*

Since its introduction here, NSV has been well-received by physicians and patients alike. In a group of 111 physicians who learned the technique through the AVSC, more than 80% reported that NSV produced less bleeding, and more than 70% indicated that patients experienced less pain during and after the procedure than with conventional vasectomy.<sup>†</sup>

Though traditional vasectomy reversal has been possible in 95% of men and pregnancy

\*Nirapathpongporn A, Huber DH, Krieger JN: No-scalpel vasectomy at the King's birthday vasectomy festival. *Lancet* 1990;335:894-895.

\*Li SQ, Goldstein M, Zhu J, et al: The no-scalpel vasectomy. *J Urol* 1991;145:341-344.

†Gonzales B, Marston-Ainley S, Vansintjejan G, et al: *No-Scalpel Vasectomy: An Illustrated Guideline for Surgeons*. New York, The Association for Voluntary Surgical Contraception, 1992.

### What's next: Lasers for vasectomy?

While visiting China in 1985 as part of an international team of experts, Marc Goldstein, MD, professor of urology and director of the center for male reproductive medicine and microsurgery at New York Hospital-Cornell Medical Center, first observed no-scalpel vasectomy (NSV). At the same time and on subsequent visits, he witnessed various percutaneous techniques, including chemical and pellet injections, that transform vasectomy into an almost nonsurgical procedure.

Dr. Goldstein was interested in the concept but had to adapt it to American needs, since the chemicals used in percutaneous techniques in China are not approved for use in the vas deferens in this country. He patented an occlusion technique called Lasocclude. Instead of injecting chemicals or pellets into the vas, the physician fires a laser through the tiny percutaneous needle.

Dr. Goldstein explains: "The surgeon steps on the laser pedal, and zap—the vas is sealed with no chemicals or cuts and without having to pull the vas out through the puncture. We've tested Lasocclude in rats; the next step is to test it in dogs because they have vasa identical to those in humans."

Laser, Dr. Goldstein says, is more effective than electrocautery for occlusion because the surgeon can control the depth of the burn. "When you occlude, you must be careful that the heat from the

burn doesn't go outside the vas and damage the blood supply to the testicle. The merit of the intravasal chemical method used by the Chinese is that nothing outside the vas is damaged. Similarly, with laser you can precisely tailor the energy and depth of the sealing activity."

Dr. Goldstein is developing another percutaneous technique, a mechanical clipping device called Vasocclude. "During NSV, the surgeon reaches through the puncture, pulls out the vas, and seals it on the outside of the scrotum," he explains. "With Vasocclude, sealing takes place inside the scrotum. The device is inserted through a slightly larger puncture hole, encircles the vas, and fires a series of clips." Vasocclude has been successfully tested in dogs and is awaiting human clinical trials.

At present, Dr. Goldstein and the Population Council's Center for Biomedical Research, located on the campus of New York's Rockefeller University, are searching for a manufacturer for Vasocclude. Dr. Goldstein says, "Because of legal concerns, it's difficult to get funding or find a manufacturer willing to commercialize any contraceptive device. And the fact that Vasocclude is used to sterilize males poses an additional problem. Most of the large multinational companies that have the resources to develop contraceptives are run by men, and men would rather let women take responsibility for contraception."

## No-scalpel vasectomy

rates after reversal have varied from 60% to 70%, NSV must be considered a permanent procedure. Men should be counseled to undergo vasectomy only if they want to become sterile.

### ON THE HORIZON

Developing countries need massive, cost-effective sterilization programs and have been instrumental in devising new methods of vasectomy. Techniques of vasal occlusion now being investigated include percutaneous elec-

trocautery and laser, intravasal injection of polyurethane pellets and cyanoacrylate-phenol, and percutaneous clipping (see "What's next: Lasers for vasectomy?" page 69).

Percutaneous vasectomy, regardless of occlusion technique, differs from NSV after the point where the vas is fixed under the skin with the three-finger method. Instead of pulling out the vas as a loop and severing it, the surgeon introduces a small needle through the skin and through the wall of the vas, puncturing the lumen. Red dye is inject-

### No-scalpel vasectomy: For more information

American Academy of Family Physicians  
8880 Ward Pkwy.  
Kansas City, MO 64114  
(800) 274-2237 or  
(816) 333-9700  
Fax: (816) 822-0907

American Cancer Society  
1599 Clifton Rd. NE  
Atlanta, GA 30329-4251  
(800) 227-2345 or  
(404) 320-3333  
Fax: (404) 636-5567

American Urological Association  
1120 N Charles St.  
Baltimore, MD 21201-5559  
(410) 727-1100  
Fax: (410) 625-2390

Association for Voluntary Surgical Contraception  
79 Madison Ave., 7th floor  
New York, NY 10016  
(212) 561-8000  
Fax: (212) 779-9439

Krames Communications  
1100 Grundy Lane  
San Bruno, CA 94066-3030  
(800) 333-3032 or  
(415) 742-0400  
Fax: (415) 244-4512

National Procedures Institute  
4909 Hedgewood Dr.  
Midland, MI 48640  
(800) 462-2492 or  
(517) 631-4664  
Fax: (517) 631-2090

### Manufacturers of equipment and training materials

Advanced Meditech International, Inc.  
86-20 53rd Ave.  
Suite 1  
Flushing, NY 11373  
(718) 672-7150  
Fax: (718) 672-8501

BEI/Meditron  
83 Hobart St.  
Hackensack, NJ 07601  
(800) 527-3530 or  
(201) 489-4222  
Fax: (201) 488-5506

BEI/ZSI  
21540-B Prairie St.  
Chatsworth, CA 91311  
(800) 223-4740 or  
(818) 700-0090  
Fax: (818) 700-0575

Creative Health Communications  
809 Elm St.  
Essexville, MI 48732  
(517) 892-7614  
Fax: (517) 893-0708

ed into the right vas and blue dye into the left. Once the liquid is going smoothly into the vas and the needle is in the proper position, the surgeon injects 0.2 mL of cyanoacrylate-phenol, a substance approximating Krazy Glue, into the vasal lumen. This chemical plug seals the vas.

When the patient voids, brown urine means that the surgeon's needle successfully entered both vasa. Red urine means the blue side was missed, and vice versa. If the patient voids yellow, both sides were missed. Close to 1 million men in China have undergone intravasal chemical injection. A zero sperm count has been the result 95% of the time.\*

A similar technique, tested in China, involves intravasal injection of a small pellet of polyurethane. Although the plug doesn't stick to the wall of the vas, it apparently seals the vas tightly enough that sperm cannot pass through. But in a study of 500 men who had this procedure, the failure rate was 50%.<sup>†</sup> The pregnancy rate following pellet removal approached 60% when the plugs were removed during the first few years following vasectomy.<sup>‡</sup>

The pellet-injection method is unique in that, theoretically, the pellet can be removed when desired, obviating the need for the technically demanding vasectomy reversal procedure. Men in a country like the United States, where the divorce rate approaches 50%, may find this "reversibility" appealing. Nevertheless, the long-term effectiveness, potential carcinogenicity, and true reversibility of the pellet-injection method are not yet clear.

\*Li SQ: Clinical application of vas deferens puncture. *Chin Med J (Engl)* 1980;93(1):69-70.

<sup>†</sup>Lue Y, Qiu A, Cai Y, et al: The mechanism of the reversible injection occlusion of vas deferens. *J Reprod Med (China)* 1994;3:30-31.

<sup>‡</sup>Zhao SC: Vas deferens occlusion by percutaneous injection of polyurethane elastomer plugs: Clinical experience and reversibility. *Contraception* 1990;41:453-459.



## TRAINING

NSV requires training, skill, and experience. The AAFP, the AVSC, and the National Procedures Institute offer seminars, hands-on workshops, and in-office instruction (see "No-scalpel vasectomy: For more information," page 70).

The for-credit AAFP presentation is intended for physicians experienced in performing vasectomy. The course includes a two-hour update addressing patients' concerns, counseling, complications, and rever-

sals. This is followed by a break-out session, during which the faculty guides participants through the procedure using a scrotal model enhanced by videos and slides. This exposure to NSV is intended to prepare the participant for clinical training in his or her own practice under the guidance of a preceptor.


Similarly, the AVSC workshop includes a three-hour lecture and videotape session, followed by hands-on work with a plastic model. Afterward, an AVSC trainer assists the physician in performing the procedure on patients in the office. □

**REFERENCES FOR** Goldstein M: No-scalpel vasectomy: A kinder, gentler approach. (DL Pennachio, ed) *Patient Care* December 15, 1994, pp 55-73.

1. Alderman PM: Complications in a series of 1,224 vasectomies. *J Fam Pract* 1991;33:579-584.
2. Bachrach CA, Mosher WD: Use of contraception in the United States, 1982. *Adv Data* 1984;102:1-8.
3. Denniston GC, Kuehl L: Open-ended vasectomy: Approaching the ideal technique. *J Am Board Fam Pract* 1994;7:285-287.
4. Forrest JD, Fordyce RR: US women's contraceptive attitudes and practice: How have they changed in the 1980s? *Fam Plann Perspect* 1988;20:112-118.
5. Franks AL, Beral V, Cates W Jr, et al: Contraception and ectopic pregnancy risk. *Am J Obstet Gynecol* 1990;163(4 pt 1):1120-1123.
6. Giovannucci E, Ascherio A, Rimm EB, et al: A prospective cohort study of vasectomy and prostate cancer in US men. *JAMA* 1993;269:873-877.
7. Giovannucci E, Tosteson TD, Speizer FE, et al: A retrospective cohort study of vasectomy and prostate cancer in US men. *JAMA* 1993;269:878-882.
8. Gonzales B, Marston-Ainley S, Vansintjean G, et al: No-Scalpel Vasectomy: An Illustrated Guideline for Surgeons. New York, The Association for Voluntary Surgical Contraception, 1992.
9. Healy B: From the National Institutes of Health: Does vasectomy cause prostate cancer? *JAMA* 1993;269:2620.
10. Kendrick JS, Gonzales B, Huber DH, et al: Complications of vasectomies in the United States. *J Fam Pract* 1987;25:245-248.
11. Li S: Some experience with vasal sterilization training programme. Presented at the First International Symposium on No-Scalpel Vasectomy, Bangkok, Thailand, 1989.
12. Li SQ: Clinical application of vas deferens puncture. *Chin Med J (Engl)* 1980;93(1):69-70.
13. Li SQ, Goldstein M, Zhu J, et al: The no-scalpel vasectomy. *J Urol* 1991;145:341-344.
14. Linnet L: Clinical immunology of vasectomy and vasovasostomy. *Urology* 1983;22:101-114.
15. Lue Y, Qiu A, Cai Y, et al: The mechanism of the reversible injection occlusion of vas deferens. *J Reprod Med (China)* 1994;3:30-31.

16. Moller H, Knudsen LB, Lynge E: Risk of testicular cancer after vasectomy: Cohort study of over 73,000 men. *BMJ* 1994;309:295-299.
17. Mosher WD: Contraceptive practice in the United States, 1982-1988. *Fam Plann Perspect* 1990;22:198-205.
18. Nienhuis H, Goldacre M, Seagroatt V, et al: Incidence of disease after vasectomy: A record linkage retrospective cohort study. *BMJ* 1992;304:743-746.
19. Nirapathpongorn A, Huber DH, Krieger JN: No-scalpel vasectomy at the King's birthday vasectomy festival. *Lancet* 1990;335:894-895.
20. Plummer JL, Fowler GC: *Procedures for primary care physicians*. St. Louis, Mosby, 1994.
21. *Population Reports*. Population Information Program. Baltimore, The Johns Hopkins University Press, March 1992, p 21.
22. Schuman LM, Coulson AH, Mandel JS, et al: Health status of American men: A study of post-vasectomy sequelae. *J Clin Epidemiol* 1993;46:697-958.
23. Sidney S, Quesenberry CP, Sadler MC, et al: Vasectomy and the risk of prostate cancer in a cohort of multiphasic health-checkup examinees: Second report. *Cancer Causes Control* 1991;2:113-116.
24. Smith JC, Cranston D, O'Brien T, et al: Fatherhood without apparent spermatozoa after vasectomy. *Lancet* 1994;344:30.
25. Viddeleer AC, Lycklama A, Nijeholt GA: Lethal Fournier's gangrene following vasectomy. *J Urol* 1992;147:1613-1614.
26. Zhao SC: Vas deferens occlusion by percutaneous injection of polyurethane elastomer plugs: Clinical experience and reversibility. *Contraception* 1990;41:453-459.

## PATIENT INFORMATION



What you should know  
about vasectomy

page 74



FROM  
YOUR DOCTOR

# What you should know about vasectomy

**A** vasectomy is simple surgery that makes a man sterile, or unable to make a woman pregnant. During a vasectomy, the doctor cuts and blocks the vas deferens. They are the two tubes that carry sperm. A vasectomy blocks sperm from becoming part of semen, and sperm are necessary for pregnancy to occur.

## What is no-scalpel vasectomy?

In a regular vasectomy, the surgeon makes one or two incisions in the scrotum with a scalpel. In the no-scalpel method, only one small puncture is made in the scrotum. The doctor reaches through that opening to get to each vas. Both types of vasectomy are very safe.

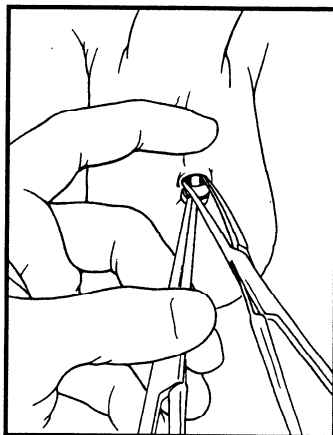
## Will there be a change in my semen?

You won't notice any difference. Vasectomy does not affect the amount, smell, or feel of the ejaculate. Semen contains only 3% sperm.

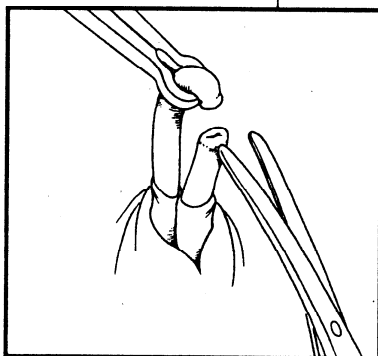
## Will I be sterile right away?

No. You can still make a woman pregnant after the operation. There are sperm above the area where each vas is cut and blocked, and these sperm will live for a while. Keep using birth control until the doctor tells you it is safe to stop.

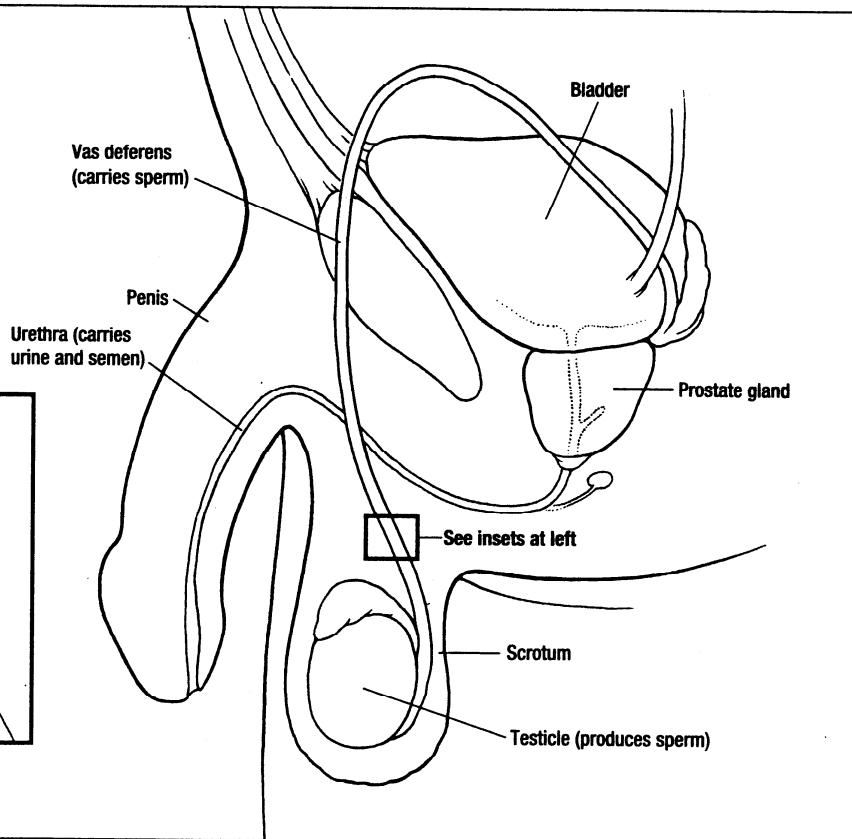
The doctor will determine when your semen is clear of sperm by checking a sperm count at least four weeks after the vasectomy. A second count is done two weeks later. When



The surgeon reaches through an opening to gain access to each vas.



Drawing the vas through the opening, the surgeon cuts and seals it so no sperm can travel through.



patient  
care

This patient information sheet may be photocopied for distribution by physicians to their patients. Written permission is required for any other use.

# What you should know about vasectomy

*continued*

both counts are zero, the vasectomy is a success.

## **Can I change my mind later?**

Vasectomy should be considered permanent. But microsurgical reversal—a long, expensive procedure—can be successful if done by an experienced microsurgeon. Before you decide to have a vasectomy, be sure you don't want more children—even if you should lose your present family. Talk over your decision with your partner.

## **How soon can I have sex?**

Do not have a sexual climax for seven days following the surgery. The scar plug that forms to block the vas

doesn't become solid until then. The pressure of an ejaculation could burst the scar tissue, causing the operation to fail. Having an erection, though, will not affect healing.

## **How soon can I go back to work?**

It depends on the type of work you do. You should rest at home all day following the surgery. Don't lift more than 10 pounds for three days after the vasectomy. The day after surgery, walking is usually allowed, and most men can return to office work. If your job requires physical labor, your doctor will probably recommend waiting for three days after surgery. ☐

## **How will I feel afterward?**

- Your scrotal area will be numb for about 6-8 hours after having the vasectomy.

- ☐ Apply ice packs during this time.
- ☐ Lie on your back as much as possible for the first day.
- ☐ Wear an athletic supporter for the next two days to ease discomfort and protect the dressing.

- Bleeding and some bruising of the scrotum and genital area may result but should disappear within a week. Serious bleeding is extremely rare.

- ☐ Avoid heavy lifting for a week.
- ☐ As a precaution, don't take aspirin for a week before the operation. Take acetaminophen instead if needed.

- You may feel mild aching in the testicles during sexual arousal for a few months following the vasectomy.

- Inflammation of the tubes coming from the testicles may occasionally occur. This is treated with medication.

- Inflammation of the scrotum is minimized by the no-scalpel technique, but infection may occur with any type of surgery. If you have excessive tenderness, swelling, fever, or oozing of pus, call your doctor right away. An athletic supporter, ice, and anti-inflammatory drugs can help.

- A small lump, called a sperm granuloma, may develop where the vas was cut. If it gets painful or larger than 1/2 inch, call the doctor.



# Marc Goldstein, M.D., F.A.C.S.

Cornell University  
Weill Medical College  
Cornell Institute for Reproductive Medicine  
Center for Male Reproductive Medicine and Microsurgery



**Marc Goldstein, M.D., F.A.C.S.** is Professor of Reproductive Medicine and Professor of Urology at Weill Medical College of Cornell University; Surgeon-in-Chief, Male Reproductive Medicine and Surgery; Executive Director, Men's Service Center of the Institute for Reproductive Medicine and Director of the Center for Male Reproductive Medicine and Microsurgery at the New York Weill Cornell University Medical Center. He is Senior Scientist with the Population Council's Center for Biomedical Research, located on the campus of Rockefeller University.

Dr. Goldstein is the only male infertility specialist cited in the American Health Magazine special issue on ***The Best Doctors in America***. He is listed in New York Magazine's June 2006 issue, ***Best Doctors in New York***. He is listed in the books ***Best Doctors in America*** (2007), The Castle Connolly Guide ***America's Top Doctors*** (2007) and ***How to Find the Best Doctors***, New York Metro Area (2006), as well as ***Who's Who in America*** (2007). He is a board certified urologic surgeon and member of a dozen national and international medical societies dealing with male infertility and reproduction. He is Past-President of the Society for Male Reproduction and Urology of the American Society for Reproductive Medicine, and recipient of the 1997 ***Master Teacher in Urology Award*** and the 2002 ***Distinguished Alumni Achievement Award*** from his alma mater. He has been honored by RESOLVE and the American Infertility Association for his "***Outstanding Dedication and Commitment to Family Building***". He is the recipient of the 2002 ***John Kingsley Lattimer Award in Urology*** from the Kidney and Urology Foundation of America.

Dr. Goldstein is internationally renowned for his pioneering work in vasectomy reversals and microsurgical repair of varicoceles and blockages. He has performed over 1,000 microsurgical vaso-vasostomies and vaso-epididymostomies. His technique of microsurgical vasectomy reversal, as published in a peer-reviewed journal, yields the highest reported sperm return and pregnancy rates. He developed the microsurgical technique of varicocelectomy in 1984 and has performed over 3000 cases with the lowest reported failure and complication rates. He was the first American surgeon to be trained in, and perform, the Chinese method of No-Scalpel Vasectomy.

Dr. Goldstein has authored or co-authored over 225 journal articles and book chapters. He is the author of ***Surgery of Male Infertility*** (1995), the first textbook on the subject, and editor of ***Atlas of the Urologic Clinics of North America: Surgery for Male Infertility***, 1999 and ***Atlas of Clinical Urology: Infertility section***, 1999. He is co-author of ***The Couple's Guide to Fertility*** (Broadway/Random House 2001, 3<sup>rd</sup> edition), ***Vasectomy Book*** and ***Reproductive Medicine Secrets*** (Hanley & Belfus, 2004). He is on the editorial boards of the medical journals ***Microsurgery*** and ***Journal of Andrology***. He has also been featured in interviews on numerous major media outlets including NBC's ***The Today Show***, ABC's ***Good Morning America***, ABC's ***Eyewitness News***, ***Newsweek*** and ***The New York Times***.

A ***summa cum laude*** graduate of the College of Medicine, State University of New York – Downstate Medical Center in Brooklyn, New York, Dr. Goldstein worked as a resident in general surgery at Columbia Presbyterian Hospital in New York. After three years overseas in the U.S. Air Force, attaining the rank of Major and flying in F4 Phantom aircraft as a Flight Surgeon, Dr. Goldstein was trained in urology at Downstate Medical Center. He continued his post-graduate training in reproductive physiology at the Population Council, Center for Biomedical Research, located on the campus of Rockefeller University, and at the Rockefeller University Hospital.

Dr. Goldstein is a long distance runner and triathlete who races regularly and has completed 20 New York City Marathons.

Dr. Goldstein's office address is: Institute for Reproductive Medicine, Weill-Cornell Medical College, Box 580, 525 E 68<sup>th</sup> Street, New York, NY 10065. The telephone number to make an appointment is (212) 746-5470. The fax number is (212)746-0977. For further information about his male infertility practice, please visit his website at [www.maleinfertility.org](http://www.maleinfertility.org).

*"State-of-the-Art Compassionate Care for the Infertile Couple"*