

## MICROSURGICAL REPAIR OF THE ADOLESCENT VARICOCELE

GARY E. LEMACK, ROBERT G. UZZO, PETER N. SCHLEGEL AND MARC GOLDSTEIN\*

*From the James Buchanan Brady Foundation, Department of Urology, New York Hospital-Cornell Medical Center and Population Council, Center for Biomedical Research, Rockefeller University, New York, New York*

### ABSTRACT

**Purpose:** Since clinically apparent varicoceles may affect testicular volume and sperm production, early repair has been advocated. However, repair of the pediatric varicocele with conventional nonmagnified techniques may result in persistence of the varicocele after up to 16% of these procedures. Also testicular artery injury and postoperative hydrocele formation can occur after nonmagnified repair. The microsurgical technique has been successfully completed in a large series of adults with a dramatic reduction in complication and recurrence rates. We report our experience with the microsurgical technique in boys.

**Materials and Methods:** A total of 30 boys (average age 15.9 years) underwent 42 microsurgical varicocelectomies (12 bilateral). All patients had a large left varicocele. Indications for repair included testicular atrophy (size difference between testicles of greater than 2 ml.) in 20 boys, pain in 5 and a large varicocele without pain or testicular atrophy in 5. Six boys were referred following failure of conventional nonmicrosurgical techniques. All boys were examined no sooner than 1 month postoperatively (mean followup 12).

**Results:** Preoperative volume of the affected testis averaged 13.0 ml., and an average size discrepancy between testicles of 2.8 ml. was noted before unilateral varicocelectomy. No cases of persistent or recurrent varicoceles were detected, and 1 postoperative hydrocele resolved spontaneously. After unilateral varicocelectomy the treated testes grew an average of 50.1%, while the contralateral testes grew only 23%. Overall, 89% of patients with testicular atrophy demonstrated reversal of testicular growth retardation after unilateral varicocelectomy. In contrast, both testes showed similar growth rates after bilateral varicocelectomy (45% left testis, 39% right testis).

**Conclusions:** The meticulous dissection necessary to preserve arterial and lymphatic supply, and to ligate all spermatic veins in the pediatric patient is readily accomplished using a microsurgical approach, and results in low recurrence and complication rates. Rapid catch-up growth of the affected testis after microsurgical varicocelectomy suggests that intervention during adolescence is effective and warranted.

**KEY WORDS:** varicocele, microsurgery, testis

The prevalence of varicoceles in the pediatric population has been estimated to be 6% at age 10 years and 15% by age 13 years, which is similar to the prevalence among men.<sup>1</sup> Clinically apparent varicoceles in children have been shown to retard the growth of the ipsilateral testis. Since testicular volume has been demonstrated to correlate with sperm production, a size discrepancy between the testes associated with a unilateral varicocele suggests a potential risk to future fertility.<sup>2</sup> The current consensus is that boys with testicular atrophy (testicular size discrepancy of greater than 2 ml.), a large varicocele, bilateral varicoceles and, perhaps, an abnormal gonadotropin-releasing hormone stimulation test undergo varicocele repair to prevent subsequent fertility problems.<sup>3-5</sup>

The conventional treatment for varicoceles in childhood has been high ligation of the internal spermatic veins via a retroperitoneal (Palomo) approach. This procedure generally involves incision of the external oblique fascia, and cephalad retraction of the internal oblique fascia and muscle to expose the spermatic cord in the retroperitoneum. The internal spermatic veins are then visually identified and ligated. No attempt

is made to identify the testicular artery. It has been suggested that the outcome of varicocelectomy in children has not been as favorable as results reported in adults due to technical difficulties in identifying small internal spermatic veins and failure to visualize aberrant external spermatic veins rejoining the internal spermatic vein above the retroperitoneum. Some authors have reported a recurrence rate as high as 16% in children, while in adults a 5% rate has been estimated.<sup>6</sup> Atassi et al recently reported a 1.3% persistence rate following varicocelectomy by intentionally ligating the testicular artery as well as visible dilated internal spermatic veins.<sup>7</sup> Postoperative hydroceles occur after 3 to 33% of standard surgical varicocele repairs (average 7%), although a breakdown of hydrocele development by age group has not been reported. Additionally, while the incidence of testicular artery injury is unknown, it is likely to be a more frequent phenomenon than realized.

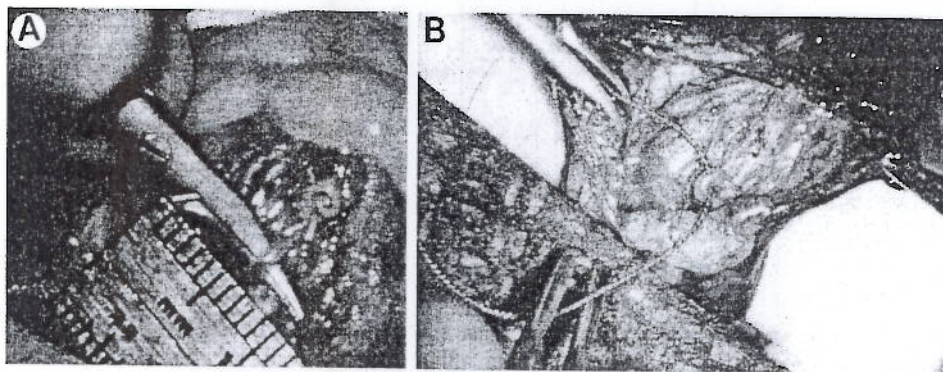
A microsurgical inguinal or subinguinal technique for the treatment of varicoceles has recently been described.<sup>8-10</sup> This surgical approach has been shown to result in fewer recurrences and postoperative complications than conventional inguinal varicocelectomy in adults. The procedure is safe to perform and, due to the ability to complete meticulous dissection of the spermatic cord elements under 6 to 25× magnification, the internal spermatic artery and lymphatics are almost always preserved. Delivery of the testis and use of magnification allow direct visual access to all possible routes

Accepted for publication February 6, 1998.

Read at annual meeting of American Urological Association, New Orleans, Louisiana, April 12-17, 1997.

\* Requests for reprints: Department of Urology, Box 94, New York Hospital-Cornell Medical Center, 525 East 68th St., New York, New York 10021.





A, testicular artery (1 mm. in diameter) identified under 15 $\times$  magnification. B, isolated with 1-zero silk suture

of venous return. We describe our application of this approach for the treatment of varicoceles in adolescents.

#### MATERIALS AND METHODS

**Patients.** A total of 30 boys 11 to 20 years old (average age 15.9) underwent microsurgical varicocelectomy. All patients had large left varicoceles, and 12 had mild to moderate right varicoceles on further evaluation. Since we believe that these smaller right varicoceles may affect testicular function and most of these patients had already experienced contralateral atrophy, all 12 underwent bilateral repair. The most common indications for repair were size difference between testicles of greater than or equal to 2 ml. with or without pain in 20 boys, pain in 5 and a large varicocele alone without pain or testicular atrophy in 5. Varicocele recurrence followed failed radiographic internal spermatic vein embolization in 2 of 6 patients who were referred to us. All patients were examined in a warm room in the supine and upright positions with and without the aid of a Valsalva maneuver. Preoperative assessment of testicular volume was performed with an orchidometer.

**Procedure.** All patients underwent bilateral or unilateral microsurgical varicocelectomy with delivery of the testis as previously described.<sup>9,10</sup> Briefly, a 2 cm. incision is made in the skin lines overlying the external inguinal ring and Scarpa's fascia is incised exposing the spermatic cord, which is grasped with a Babcock clamp as it exits the external ring, delivered and surrounded with a large Penrose drain. In prepubertal boys the external oblique aponeurosis is opened and T6 cord is dissected near the internal ring. The testis is delivered, and all external spermatic and gubernacular veins are ligated or clipped and divided. The testis is returned to the scrotum and the spermatic cord is placed over the Penrose drain. Using the operating microscope under 6 to 25 $\times$  power magnification, the external and internal spermatic fascias are opened. The testicular and cremasteric arteries and lymphatics are identified and preserved (see figure). All spermatic veins are doubly ligated with small hemoclips or 4-zero silk sutures and divided. The vas deferens and its vessels are preserved.

General endotracheal anesthesia was used in all patients, and for all but 1 hospital discharge was the same day. There were 12 patients who underwent bilateral procedures and the remainder underwent left varicocelectomy. Simultaneous contralateral orchiopexy and contralateral hydrocelectomy were done in 1 patient each at the time of varicocelectomy.

#### RESULTS

Preoperative testicular volume in our patients ranged from 1.5 to 20 ml. (total 42 testes treated, average 13 ml.). When unilateral varicocelectomy was planned the average size discrepancy between the 2 sides was 2.8 ml. Semen analyses before the planned varicocelectomy in 2 patients 18 and 19

years old demonstrated below average sperm concentrations (average 32.4 million per ml.).

All but 1 of the 30 patients who underwent varicocele repair were seen at followup at least 1 month postoperatively and no recurrences were detected. A single hydrocele at 2 months postoperatively had resolved spontaneously by 11 months after varicocele repair. A second patient experienced scrotal pain postoperatively, which resolved after a short course of doxycycline and ibuprofen.

Longer term followup was available in 13 patients, all of whom still had no evidence of recurrence (median followup 7 months, range 4 to 48). Of these patients 7 had undergone left and 6 bilateral varicocelectomy. All patients had subsequent growth of the affected and treated testis (19 testes) with an average growth of 51% above preoperative size. In comparison, the untreated testis grew an average of 23% in the same time, which was significantly different between groups ( $p = 0.027$ , Student's  $t$  test). In patients who had undergone unilateral varicocelectomy the average growth of the treated testis was 66% while the contralateral untreated side experienced less growth (23%), which was significantly different between groups ( $p = 0.01$ ). Among the 6 boys who underwent bilateral varicocelectomy both testes demonstrated similar growth at an average followup of 10 months (45% left testis, 39% right testis), which is not significantly different between sides.

#### DISCUSSION

The association between a varicocele in the pediatric patient and subsequent subfertility is suggested by several studies. Lyon et al noted that testicular growth retardation occurred in 10% of testes affected by a varicocele in pediatric patients, and that 20% of adult patients had reduced size of the left testis compared to the right in the presence of a left varicocele.<sup>11</sup> Taken together with the inability of the varicocele repair to restore normal fertility for all men after varicocelectomy in adulthood, these results suggest that an insult to peripubertal testicular growth may have a permanent effect on future fertility. Lipshultz and Corriere demonstrated a size reduction in the ipsilateral and contralateral testis in subfertile men with varicoceles, and proposed that surgical correction at an early age could prevent subsequent atrophy.<sup>12</sup> Finally, Sigman and Jarow recently argued for repair of adolescent varicoceles that were associated with growth retardation based on the finding of significantly poorer mean motile sperm counts in men presenting with varicocele associated testicular hypotrophy.<sup>13</sup>

The ability of adolescent varicocele repair to reverse testicular growth retardation in 80% of treated patients combined with our findings support the value of early varicocele repair.<sup>5</sup> In patients whose only indication was a size discrepancy of greater than 2 cc between the testes the affected testicular volume was shown to increase an average of 64%



as opposed to the untreated testis, which grew an average of 26% in the same time. These results suggest that early surgical intervention served to promote testicular growth of the affected side. In 8 of 9 patients size discrepancy of greater than 2 ml. between testes preoperatively resolved after surgical repair of the varicocele.

The microsurgical technique for the repair of varicoceles has proved to be an effective and safe method of treatment in adults. Varicoceles in children potentially pose an even more difficult problem because of the reduced size of the internal spermatic veins and lymphatics, and a diminished arterial pulse. The advantages gained by using the operating microscope in the adult could clearly benefit the potentially more challenging repair of the pediatric varicocele. Use of the operating microscope and delivery of the testis allow identification and preservation of the testicular artery and lymphatics as well as direct visual access to all possible routes of venous return.

We have demonstrated that this repair can be performed in a pediatric population on an outpatient basis through a 2 cm. subinguinal incision as safely as in adults. Intentional ligation of the testicular artery has been shown to reduce markedly the incidence of varicocele recurrence in adolescents by ensuring ligation of periarterial veins that may be missed with a nonmicroscopic approach.<sup>7</sup> Our results indicate that postoperative hydrocele formation and varicocele recurrence can be eliminated without intentional ligation of the testicular artery. Similar results following microsurgical varicocelectomy in 32 boys were recently reported by Minevich et al.<sup>14</sup> Finally, while the effect of sacrificing the testicular artery on subsequent testicular capacity in the adolescent patient remains uncertain, it is untenable that ligation of the artery is likely to enhance testicular function.

#### CONCLUSIONS

Whether to treat an asymptomatic varicocele during adolescence remains debatable among urologists. While some claim that intervention will not alter the natural history of the disease process, others have found that the continued presence of a varicocele in childhood may adversely influence testicular function and, therefore, prompt intervention is mandated, particularly when a size discrepancy between testicles is already apparent at the time of examination. Rapid catch-up growth of the affected testis after microsurgical varicocelectomy suggests that correction during adolescence may indeed enhance testicular function and is warranted. The greatest benefit was seen in patients whose affected testis was more than 2 cm. smaller than the contralateral testis.

Interestingly, the most appropriate method of repair for this age group is even more controversial. While an abundance of literature concerning adult varicoceles has effectively

demonstrated the superiority of the microsurgical technique, many still contend that the Palomo approach remains effective in the adolescent population. We have demonstrated that the meticulous dissection necessary to preserve the arterial and lymphatic supply, and to ligate all spermatic veins in the adolescent patient is readily accomplished using a microsurgical technique and that this approach results in extremely low recurrence and complication rates. Further validation of this approach will be attained by following the semen parameters of these boys as they mature.

#### REFERENCES

1. Oster, J.: Varicocele in children and adolescents. An investigation of the incidence among Danish school children. *Scand. J. Urol. Nephrol.*, **5**: 27, 1971.
2. Johnson, L., Petty, C. S. and Neaves, W. B.: The relationship of biopsy evaluations and testicular measurements to over-all daily sperm production in human testes. *Fertil. Steril.*, **34**: 36, 1980.
3. Kass, E. J., Freitas, J. E., Salisz, J. A. and Steinert, B. W.: Pituitary gonadal dysfunction in adolescents with varicocele. *Urology*, **42**: 179, 1993.
4. Steckel, J., Dicker, A. P. and Goldstein, M.: Relationship between varicocele size and response to varicocelectomy. *J. Urol.*, **149**: 769, 1993.
5. Kass, E. J. and Belman, A. B.: Reversal of testicular growth failure by varicocele ligation. *J. Urol.*, **137**: 475, 1987.
6. Gorenstein, A., Katz, S. and Schiller, M.: Varicocele in children: "to treat or not to treat"-venographic and manometric studies. *J. Ped. Surg.*, **21**: 1046, 1986.
7. Atassi, O., Kass, E. J. and Steinert, B. W.: Testicular growth after successful varicocele correction in adolescence: comparison of artery sparing techniques with the Palomo procedure. *J. Urol.*, **153**: 482, 1995.
8. Marmar, J. L. and Kim, Y.: Subinguinal microsurgical varicocelectomy: a technical critique and statistical analysis of semen and pregnancy data. *J. Urol.*, **152**: 1127, 1994.
9. Goldstein, M., Gilbert, B. R., Dicker, A., Dwosh, J. and Gnecco, G.: Microsurgical inguinal varicocelectomy with delivery of the testis: an artery and lymphatic sparing technique. *J. Urol.*, **148**: 1808, 1992.
10. Goldstein, M.: Surgical management of male infertility and other scrotal disorders. In: *Campbell's Urology*, 7th ed. Edited by P. C. Walsh, A. B. Retik, E. D. Vaughan, Jr. and A. J. Wein. Philadelphia: W. B. Saunders, chapt. 44, p. 1331-1378, 1998.
11. Lyon, R. P., Marshall, S. and Scott, M. P.: Varicocele in childhood and adolescence: implication in adulthood infertility? *Urology*, **19**: 641, 1982.
12. Lipshultz, L. I. and Corriere, J. N.: Progressive testicular atrophy in the varicocele patient. *J. Urol.*, **117**: 175, 1977.
13. Sigman, M. and Jarow, J. P.: Ipsilateral testicular hypotrophy is associated with decreased sperm counts in infertile men with varicoceles. *J. Urol.*, **158**: 605, 1997.
14. Minevich, E., Wacksman, J., Lewis, A. C. and Sheldon, C. A.: Inguinal microsurgical varicocelectomy in the adolescent: technique and preliminary results. *J. Urol.*, **159**: 1022, 1998.



## EDITORIAL: ADOLESCENT VARICOCELE

Animal and human studies have demonstrated that varicocele is associated with a progressive duration-dependent decline in testicular function.<sup>1-7</sup> Repair of varicocele will halt any further damage and in a majority of men will result in improved spermatogenesis. In adolescents<sup>8</sup> and adults<sup>9</sup> increase in testicular volume has been documented after surgical repair. Correction of adolescent varicocele is appropriate in boys with significant ipsilateral testicular growth failure. A good case can also be made for repair when the varicocele is large, associated with change in testicular consistency (softness) or symptomatic. In postpubertal adolescents repair is indicated for abnormal semen analyses, low serum testosterone and/or elevation of serum follicle-stimulating hormone levels. Since palpable varicocele is found in at least 15 to 20% of postpubertal male individuals and 23% of these varicoceles are large,<sup>10</sup> adolescents who are potential candidates for repair number in the millions worldwide. Although prophylactic varicocelectomy on a large scale sounds like a radical proposal, it is likely that the costs of treating varicocele induced infertility (after the damage has been done) will far exceed those of prophylactic repair when one factors in the costs of infertility evaluation and treatments, such as intrauterine insemination and in vitro fertilization. The potentially important role of urologists in preventing future infertility underscores the importance of using a varicocelectomy technique that minimizes the risk of complications and recurrence. This raises several questions, including whether varicoceles in children and adolescents are different than in adults, what the ideal operation is for the repair of varicocele and whether the approach to repair should be different in adolescents and adults.

The most important difference between varicocelectomy in adults and adolescents is that in most adolescents it is done for prophylaxis rather than to treat a disease. The only palpable evidence that varicocele is anatomically different in adolescents and children compared to adults is that recurrence rates after surgical repair appear to be higher in children and adolescents.<sup>11,12</sup> Logic dictates that children probably have a greater potential for neovascularization than adults, which may be the reason that surgical failure rates are higher in children. This observation may also explain the ability of the adolescent testis to survive intentional ligation of the entire testicular vascular pedicle with low morbidity, documented reversal of growth failure and a low incidence of varicocele recurrence, as reported by Atassi et al (page 482) in this issue of the Journal. These authors advocate this approach because they claim that higher failure rates occur when artery sparing techniques are used. In comparing a mass ligation Palomo technique with an artery sparing technique, reversal of growth failure was equally successful in both groups but recurrence rates were not reported. In the conclusion they state that "In our experience the Palomo procedure achieves a significantly higher surgical success rate when compared to the artery sparing technique." The reference given to support this statement is the 1960 article by Ivanissevich describing the standard inguinal technique without magnification, which is not an example of an artery sparing procedure.<sup>13</sup>

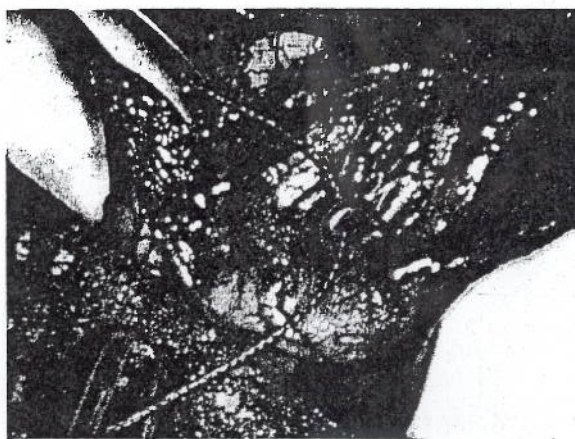
This leads to the question of the ideal technique for repair of varicocele. The following criteria are obvious: preservation of optimal testicular function, elimination of the varicocele, minimal current and future morbidity, and cost-effectiveness. Testicular volume measurement is the primary method of assessing testicular function in children and peri-pubertal adolescents. In adults, it is known that atrophy is a relatively

crude end point for seminiferous tubular injury. Impaired sperm production and maturation arrest are frequently associated with normal testicular volume. Those surgeons who ligate the testicular artery and say that it does no harm because there is no atrophy are doing a procedure with unknown effects on future spermatogenesis. This procedure is probably feasible most of the time because repair of unilateral varicocele will benefit spermatogenesis on the contralateral side, most adolescent varicocele repair is done unilaterally and children probably have a greater capacity for neovascularization than adults. At least it is inarguable that testicular artery ligation will not enhance testicular function.

In animals<sup>14,15</sup> and human adults<sup>16,17</sup> testicular artery ligation is associated with substantial morbidity. The incidence of testicular atrophy after the Ivanissevich approach without magnification is approximately 2 per 1,000. Azoospermia or severe oligospermia after nonartery sparing bilateral varicocelectomy has been reported<sup>16</sup> but the true incidence is unknown. I have seen 4 men with this complication, all of whom underwent nonmagnified procedures. However, intentional ligation of the testicular artery is associated with lower rates of varicocele recurrence, which strongly suggests that persistence of the periarterial venous network (venae comitantes) is the most common cause of varicocele recurrence. Previous studies of varicocele microanatomy support this notion.<sup>18</sup> Furthermore, microsurgical varicocelectomy techniques that preserve the testicular artery by meticulous microdissection of the periarterial venous plexus<sup>19</sup> or injection of sclerosant agents<sup>20</sup> were associated with recurrence rates of 0.6% in 640 operations and 0.8% in 606 operations, respectively. All reported series of adolescent varicocelectomy, including that reported by Atassi et al, are small and, therefore, lack sufficient statistical power for comparison to the large adult series. I have performed microsurgical inguinal varicocelectomy in 16 boys without recurrence or hydrocele. Hydrocele is the most common complication of nonmicroscopic varicocelectomy and is clearly an unpleasant sequela, necessitating surgical repair about half the time and with an average incidence of 7%,<sup>21</sup> which is almost identical to the 2 of 36 cases (6%) reported by Atassi et al. Hydrocele is due to lymphatic obstruction and preservation of lymphatics will virtually eliminate this complication.<sup>19,20</sup>

Should the approach to varicocelectomy be different in adults and adolescents or children? Why are pediatric urologists now embracing a technique that has been largely abandoned by male infertility specialists in favor of low inguinal operations using operating microscopes?<sup>22</sup> The answer to the first question is no. The goals of varicocelectomy and basic anatomy are identical in both groups. The answer to the second question is training and experience. The dramatic superiority of microsurgical techniques for vasovasotomy and vasoepididymostomy has made such training mandatory for the male infertility specialist. A subinguinal microsurgical operation can be done through a 2 to 3 cm. incision without cutting or splitting any muscle or fascia in adults or adolescents. The Palomo operation requires a larger incision through 3 muscle layers and, because the cord structures cannot be externalized, preservation of the artery is almost impossible without also preserving the periarterial venous plexus, resulting in a high incidence of varicocele recurrence. To prevent recurrence the artery must be picked absolutely clean (see figure) or ligated. It is somewhat puzzling that pediatric urologists, who are great champions of loupe magnification, are reluctant to use the microscope which, with only a little practice, is more comfortable, flexi-





Testicular artery, identified by 1-zero silk tag suture, picked clean of periarterial venae comitantes. Reduced from  $\times 15$ .

ble, and capable of providing variable and higher magnification than loupes. The testicular artery in adults varies from 0.3 to 1.0 mm. in diameter and it is even smaller in children. Loupe magnification is inadequate for its meticulous dissection. Laparoscopic varicocelectomy can provide similar advantages of high power magnification with artery and lymphatic preservation, and apparently low recurrence rates.<sup>23</sup> Laparoscopy may also be more familiar to pediatric urologists because of their experience with laparoscopic orchiopey. Laparoscopy is associated with greater potential serious morbidity than the Palomo or low inguinal microsurgical techniques. Laparoscopy also takes longer and is less cost-effective<sup>22</sup> than microsurgical low inguinal or Palomo techniques, which can be performed in 20 to 60 minutes. Radiographic occlusion techniques preserve the artery and lymphatics but have higher failure rates than surgical techniques.

An important consideration regarding varicocelectomy techniques is future vasectomy. After mass ligation of the testicular vascular pedicle, the testis depends on the deferential vessels for its blood supply. Vasectomy in men who underwent mass ligation varicocelectomy is likely to result in testicular atrophy. These men and the parents of adolescents undergoing this type of varicocelectomy must be told that they should not undergo vasectomy. Since 11.7% of couples rely on vasectomy for contraception and a half million men undergo vasectomy annually in the United States,<sup>24</sup> this is not a trifling practical or medicolegal consideration.

Whither adolescent varicocelectomy? Preservation of testicular function has traditionally been a major concern of pediatric urologists. Orchiopey is preventive medicine for infertility,<sup>25</sup> as is varicocelectomy. Techniques tested in large numbers of adults can be used in adolescents and children. At least, such techniques do not deserve to be ignored. Clearly, mass ligation of the testicular vascular pedicle can be feasible in children. Does this mean that it is the ideal technique? I think not.

Marc Goldstein  
Department of Urology  
The New York Hospital-Cornell Medical Center  
New York, New York

## REFERENCES

1. Nagler, H. M., Li, X.-Z., Lizza, E. F., Deitch, A. and deVere White, R.: Varicocele: temporal considerations. *J. Urol.*, **134**: 411, 1985.
2. Harrison, R. M., Lewis, R. W. and Roberts, J. A.: Pathophysiology of varicocele in nonhuman primates: long-term seminal and testicular changes. *Fertil. Steril.*, **46**: 500, 1986.
3. Russell, J. K.: Varicocele, age, and fertility. *Lancet*, **2**: 222, 1957.
4. Lipshultz, L. I. and Corriere, J. N., Jr.: Progressive testicular atrophy in the varicocele patient. *J. Urol.*, **117**: 175, 1977.
5. Kass, E. J., Chandra, R. S. and Belman, A. B.: Testicular histology in the adolescent with a varicocele. *Pediatrics*, **79**: 996, 1987.
6. Gorelick, J. and Goldstein, M.: Loss of fertility in men with varicocele. *Fertil. Steril.*, **59**: 613, 1993.
7. Witt, M. A. and Lipschultz, L. I.: Varicocele: a progressive or static lesion? *Urology*, **42**: 541, 1993.
8. Kass, E. J. and Belman, A. B.: Reversal of testicular growth failure by varicocele ligation. *J. Urol.*, **137**: 475, 1987.
9. Gentile, D. P. and Cockett, A. T. K.: The effect of varicocelectomy on testicular volume in 89 infertile adult males with varicoceles. *Fertil. Steril.*, **58**: 209, 1992.
10. Steckel, J., Dicker, A. P. and Goldstein, M.: Relationship between varicocele size and response to varicocelectomy. *J. Urol.*, **149**: 769, 1993.
11. Rothman, L. P., Newmark, H., III and Karson, R. A.: The recurrent varicocele—a poorly recognized problem. *Fertil. Steril.*, **35**: 552, 1981.
12. Levitt, S., Gill, B., Katlowitz, N., Kogan, S. J. and Reda, E.: Routine intraoperative post-ligation venography in the treatment of the pediatric varicocele. *J. Urol.*, **137**: 716, 1987.
13. Ivanissevitch, O.: Left varicocele due to reflux; experience with 4,470 operative cases in forty-two years. *J. Int. Coll. Surg.*, **34**: 742, 1960.
14. Fowler, R. and Stephens, F. D.: The role of testicular vascular anatomy in the salvage of high, undescended testes. In: *Congenital Malformation of the Rectum, Anus and Genito-Urinary Tracts*. Edited by F. D. Stephens. New York: Churchill Livingstone, p. 306, 1963.
15. Hsu, T. H., Huang, J. K., Ho, D. M., Liu, R. S., Chen, M. T. and Chang, L. S.: Role of the spermatic artery in spermatogenesis and sex hormone synthesis. *Arch. Androl.*, **31**: 191, 1993.
16. Silber, S.: Microsurgical aspect of varicocele. *Fertil. Steril.*, **31**: 230, 1979.
17. Penn, I., Mackie, G., Halgrimson, C. G. and Starzl, T. E.: Testicular complications following renal transplantation. *Ann. Surg.*, **176**: 697, 1972.
18. Beck, E. M., Schlegel, P. N. and Goldstein, M.: Intraoperative varicocele anatomy: a macroscopic and microscopic study. *J. Urol.*, **148**: 1190, 1992.
19. Goldstein, M., Gilbert, B. R., Dicker, A. P., Dwosh, J. and Gnecco, C.: Microsurgical inguinal varicocelectomy with delivery of the testis: an artery and lymphatic sparing technique. *J. Urol.*, **148**: 1808, 1992.
20. Marmar, J. L. and Kim, Y.: Subinguinal microsurgical varicocelectomy: a technical critique and statistical analysis of semen and pregnancy data. *J. Urol.*, **152**: 1127, 1994.
21. Szabo, R. and Kessler, R.: Hydrocele following internal spermatic vein ligation: a retrospective study and review of the literature. *J. Urol.*, **132**: 924, 1984.
22. Jarow, J. P.: Varicocele repair: low ligation. *Urology*, **44**: 470, 1994.
23. Donovan, J. F., Jr.: Laparoscopic varix ligation. *Urology*, **44**: 467, 1994.
24. Mosher, W.: Contraceptive practice in the United States, 1982–1988. *Fam. Plan. Perspect.*, **22**: 200, 1990.
25. Mininberg, D. T. and Schichman, S. J.: Pediatric orchiopey: preventive medicine for infertility. In: *Surgery of Male Infertility*. Edited by M. Goldstein. Philadelphia: W. B. Saunders Co., chapt. 24, p. 202, 1995.